



# Example Reports

## CT



Clinical  
Support  
Services



# Reporting Service: CT

Species: Canine

Breed: Border Collie

Sex: Male Entire

Age: 4 months

## Clinical History:

4 month old BC puppy that probably had some kind of traumatic incident yesterday evening. Very painful and stiff neck, epistaxis upon arrival, a bit ataxic movement. Cranial nerves ok, proprioception ok. Questions to be answered:

X-rays suspicious of trauma/luxation in the atlanto-axial joint, but very hard to position the puppy good enough for x-rays. Other findings?

Number of series / images: 3 / 1221

Series: TUNNA BONE , IDOSE (3), TUNNA SOFT, IDOSE (3), TUNNA SOFT, IDOSE (4)

Study dated: 01/Oct/2021

Study received: 01/Oct/2021

Anatomic regions: Spine C1 - T2/Neck

Details of study and technical comments: CT study of the cervical vertebral column in bone and soft tissue algorithms pre and post-contrast dated 1st October 2021. Patient in sternal decubitus. The image quality is good.

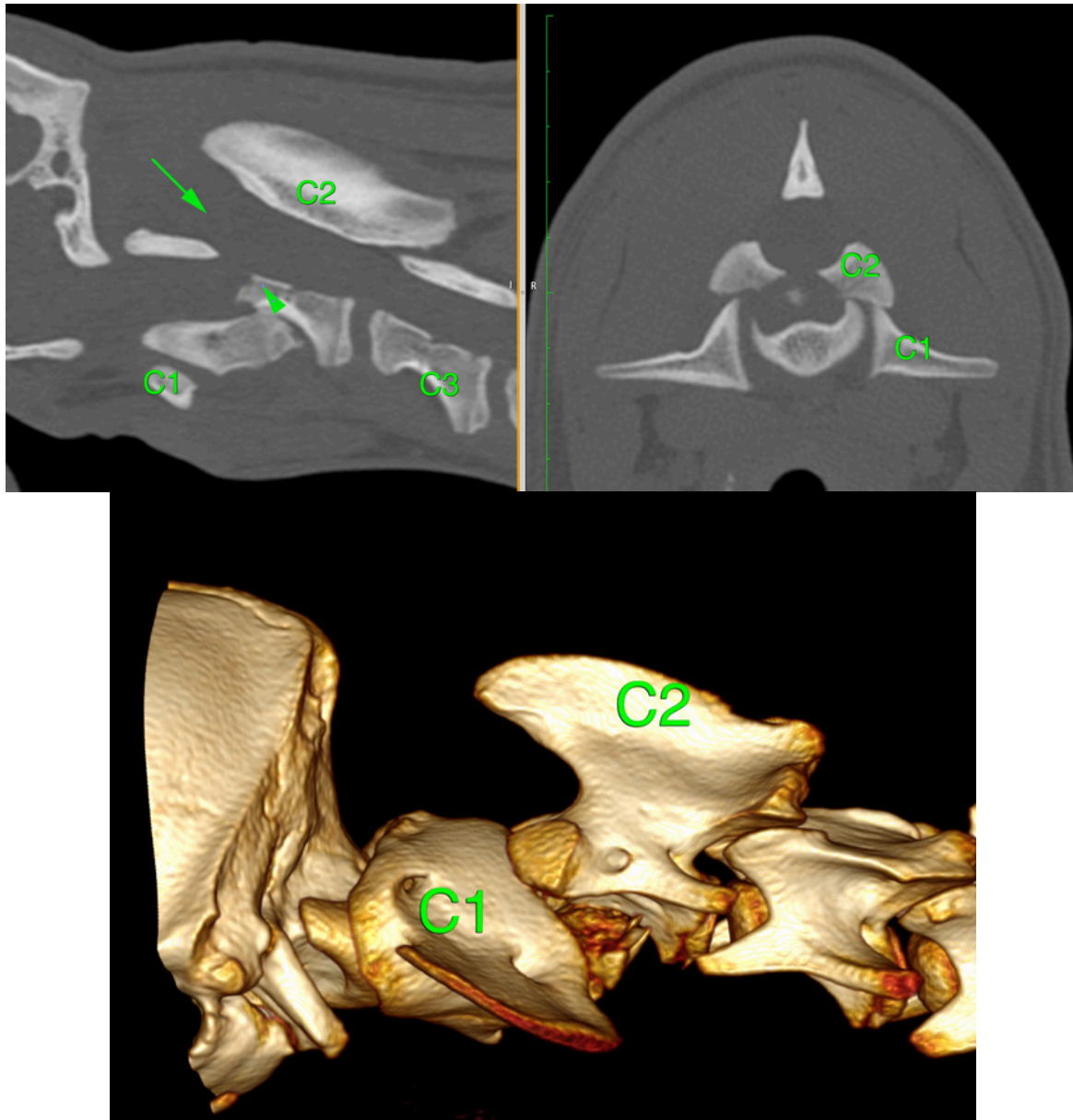
Diagnostic interpretation:



Reported by VET.CT

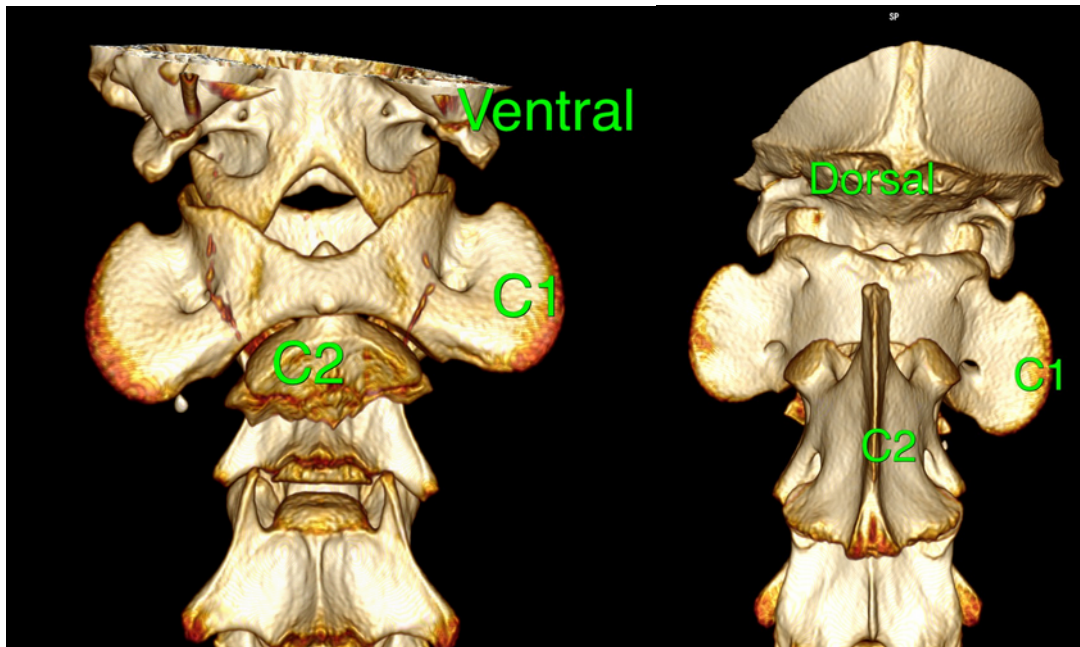
This report is based on the available history and radiographic interpretation only and not on a physical examination of the patient. It has been prepared specifically for interpretation by the currently licensed and registered veterinary surgeon responsible for the care of this patient.

There is a complete, displaced, transverse fracture in the mid portion of the body of C2, between the intercentrum 2 and the centrum 2 (green arrowhead). The margins of the fracture are sharp/pointed. The caudal part of the fractured C2 vertebral body is displaced in cranial and dorsal direction inside the vertebral canal, overriding the cranial fragment. Cranially, the fracture involves the ventral surface of the floor of the vertebral canal. Bilaterally, the fracture involves the ventrolateral aspect of the cranial articular surface of C2. The caudal fragment of C2-which contains the neural arch- is luxated in cranial and dorsal direction and overlaps the caudodorsal surface of the arch of C1 (pictures below). There is marked misalignment between the dorsal lamina of C1 and the dorsal lamina of C2. The dens of the axis has normal size, shape, contour, and attenuation. The alignment of the dens related to C1 vertebral foramen is normal with the dog in this position, but there is mild widening of the ventral articular joint space C1-C2. The transverse atlantal ligament looks intact. There is a small focus of mineral attenuation in the ventral atlantooccipital membrane with no additional abnormalities.

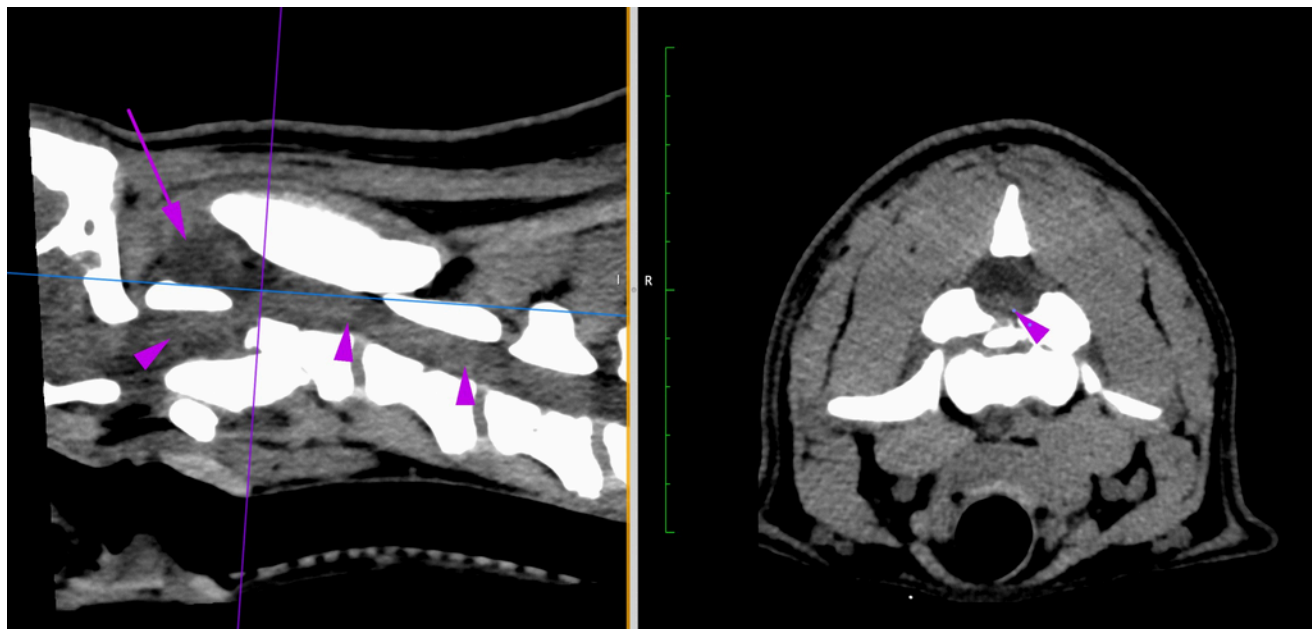


Reported by VET.CT

This report is based on the available history and radiographic interpretation only and not on a physical examination of the patient. It has been prepared specifically for interpretation by the currently licensed and registered veterinary surgeon responsible for the care of this patient.

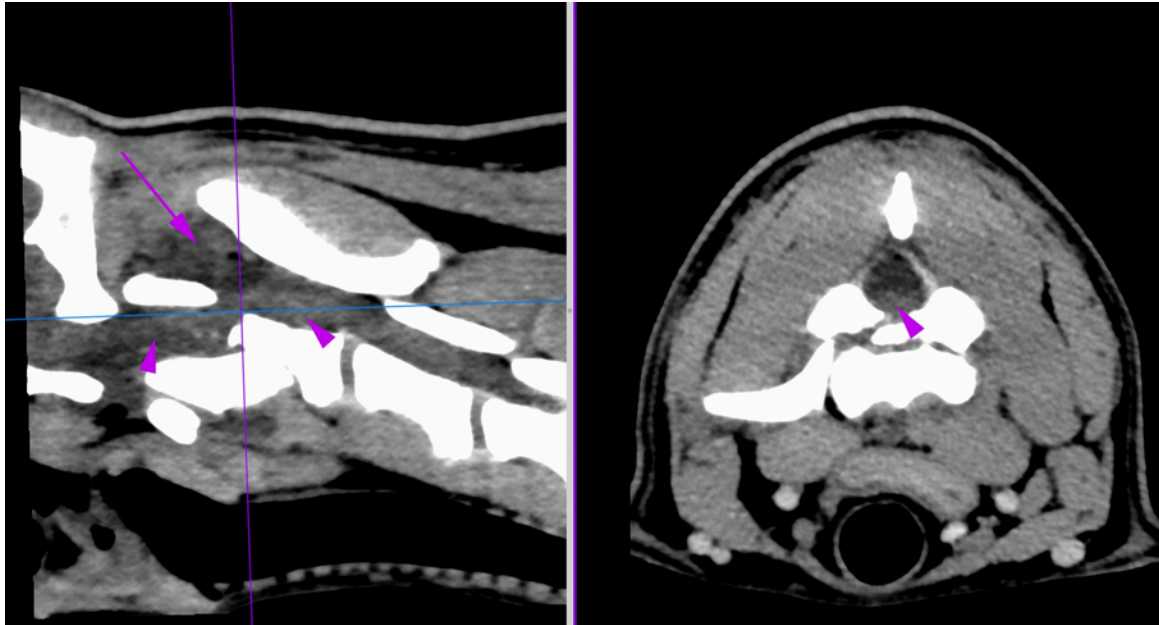


As a result of the vertebral fracture and dorsal luxation of C2, there is marked stenosis of the vertebral canal between C1 and C2, with dorsal displacement and compression of the spinal cord (magenta arrowheads). There is widening of the subarachnoid space cranial to the fracture, and the attenuation of the spinal cord is heterogeneous. Caudal to the fracture, the spinal cord looks swollen. There is distension of the C1-C2 joint space with presence of effusion (long magenta arrow).



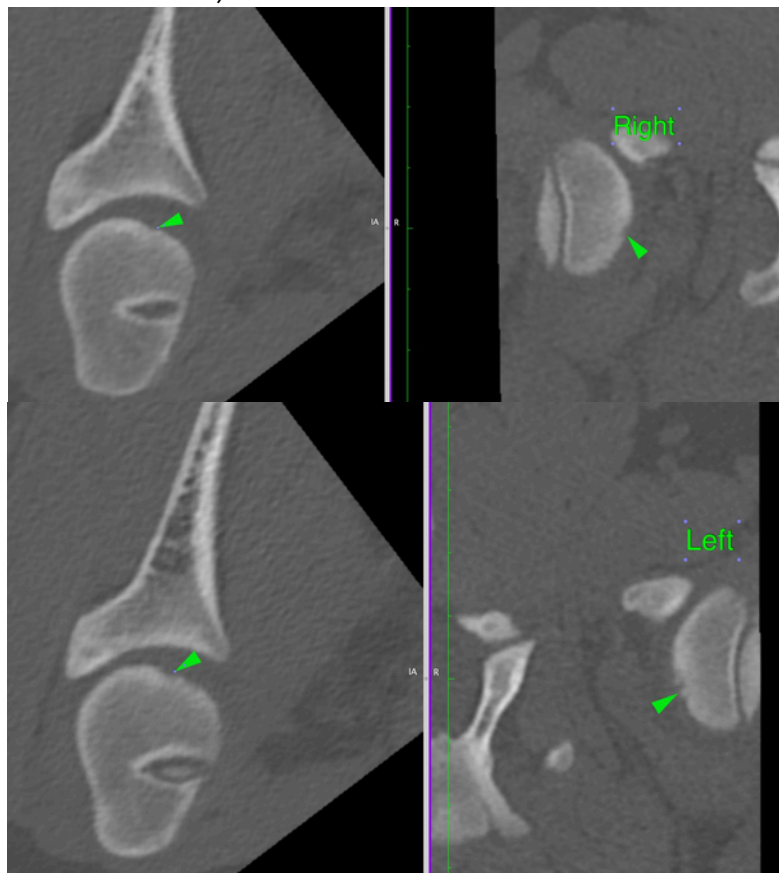
Reported by VET.CT

This report is based on the available history and radiographic interpretation only and not on a physical examination of the patient. It has been prepared specifically for interpretation by the currently licensed and registered veterinary surgeon responsible for the care of this patient.



There is increased mineral attenuation in the longus capitis muscles ventral to C2 at the fracture site, and presence of fluid attenuation in the facial planes and subcutis. The atlantooccipital joint is normal. No other fractures/fissures are detected in the vertebral column.

There are subtle irregularities in the subchondral bone of the humeral heads bilaterally (arrowheads below) with no additional abnormalities.



Reported by VET.CT

This report is based on the available history and radiographic interpretation only and not on a physical examination of the patient. It has been prepared specifically for interpretation by the currently licensed and registered veterinary surgeon responsible for the care of this patient.

There are small gas inclusions in the subcutaneous fat of the right dorsolateral cervical region.

Conclusions:

1. Acute, complete, displaced fracture of the mid portion of the vertebral body of C2 with cranial and dorsal luxation of the caudal fragment. Traumatic origin. Non-stable.

a. The fracture involves the ventral surface of the floor of the vertebral canal and the ventral aspect of the cranial articular surface bilaterally.

b. C1-C2 vertebral luxation.

c. Severe stenosis of the vertebral canal at the fracture site with severe spinal cord compression. Spinal cord oedema/contusion is expected. See comments.

d. C1-C2 joint distension/effusion.

e. Changes in the soft tissues of the neck compatible with oedema, inflammation, haematoma.

2. Small irregularities in the surface of the humeral heads: normal (young patient) vs. osteochondrosis.

3. Gas inclusions on the right lateral aspect of the neck: most likely iatrogenic. Open wounds are considered less likely.

Additional comments:

The lesion observed at C2 can explain part of the clinical signs. CT of the head can be considered to exclude additional fractures /trauma that could explain epistaxis or reveal additional lesions in the skull/brain. The status of the spinal cord cannot be completely assessed on CT. MRI would be helpful, if clinically indicated.

If you have any queries regarding this report then please "Add a comment" on the VetCT platform or contact [info@vet-ct.com](mailto:info@vet-ct.com)



Reported by VET.CT

This report is based on the available history and radiographic interpretation only and not on a physical examination of the patient. It has been prepared specifically for interpretation by the currently licensed and registered veterinary surgeon responsible for the care of this patient.



# Example Reports

## MRI



Clinical  
Support  
Services



# Reporting Service: MRI

Species: Canine      Breed: Crossbreed, large      Sex: Male Neutered      Age: 12 years, 8 months

## Clinical History:

-3 episodes of acute onset seizures that started 11/7/21. Diarrhoea in the past 2 days with several bilious vomits and showed HL weakness.

-No known access to toxins.

-Unilateral tieback L arytenoid 04/21.

-PE: Obtunded. Head tilt to L

The drugs that patient had been on prior to the MRI:

1)Mannitol 20% 0.8g/kg IV

2)Dexamethasone 0.2mg/kg IV

3)Levetiracetam 60mg/kg IV

4)Phenobarbitone 6mg/kg IV

5)Maropitant 1mg/kg IV



Reported by VET.CT

This report is based on the available history and radiographic interpretation only and not on a physical examination of the patient. It has been prepared specifically for interpretation by the currently licensed and registered veterinary surgeon responsible for the care of this patient.



6) Ondansetron 0.3mg/kg IV

7) Paracetamol 10mg/kg IV

Number of series / images: 11 / 497

Series: APPARENT DIFFUSION COEFFICIENT (MM<sup>2</sup>/S), DOR T2, LOCALIZER, SAG T2, TRANS DWI, TRANS T1 FS 3D+C, TRANS T1 SE, TRANS T1 SE C+, TRANS T2, TRANS T2 FLAIR, TRANS T2\* GRE SHIM

Study dated: 13/07/2021

Study received: 13/07/2021

Anatomic regions: Head

Details of study and technical comments: MRI of the brain with T2w, FLAIR, T1w (pre and post-contrast images), T2\* GRE and DWI sequences. Images are acquired in 3 planes. The images are of excellent quality.

Diagnostic interpretation:

BRAIN: The brain is abnormal in appearance with bilaterally symmetrical focal areas of homogenous T2 hyper-intensity within grey matter involving the caudal colliculi, vestibular nuclei, red nuclei and ventromedially in the thalamus. There are similar lesions in the midline of the ventral para-aqueductal grey matter and the cerebellar nodulus. There is no mass effect or atrophy associated with the lesions. No diffusion abnormalities are visible and there are no hemorrhages on the T2\* GRE images. On the T1w images the lesions are iso-mildly hypointense. The post-contrast images show dense, moderate enhancement of the caudal colliculi and vestibular nuclei lesions. No other abnormal enhancement is visible. The conformation of the brain is normal with no gyral or sulcal abnormalities. The rest of the grey and white matter are normal in signal intensity with no signal alterations. The ventricular system is normal in size and shape. There is a normal size and shape to the pituitary gland. No cranial nerve abnormalities are visible. The extra-cranial structures are normal.

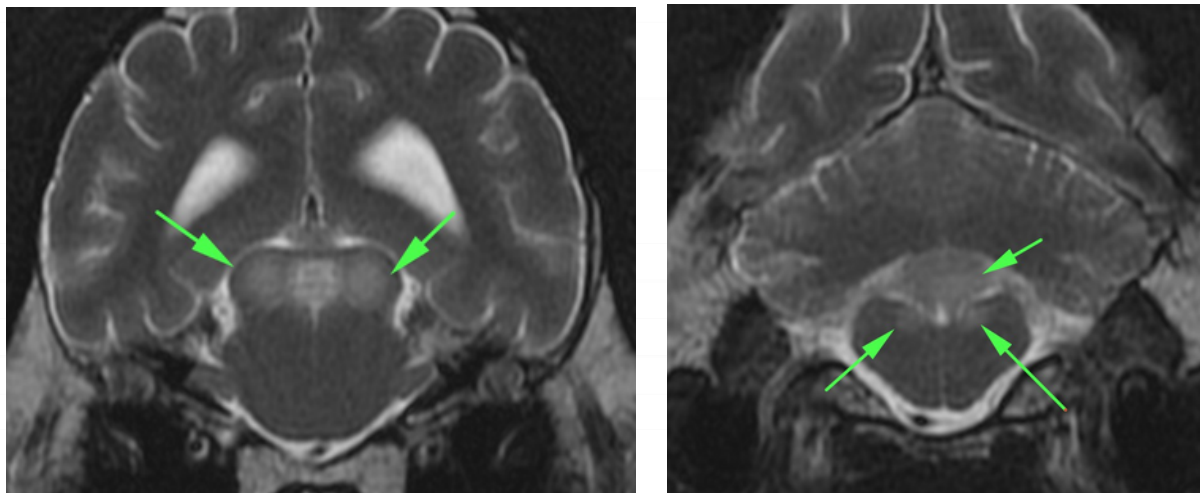
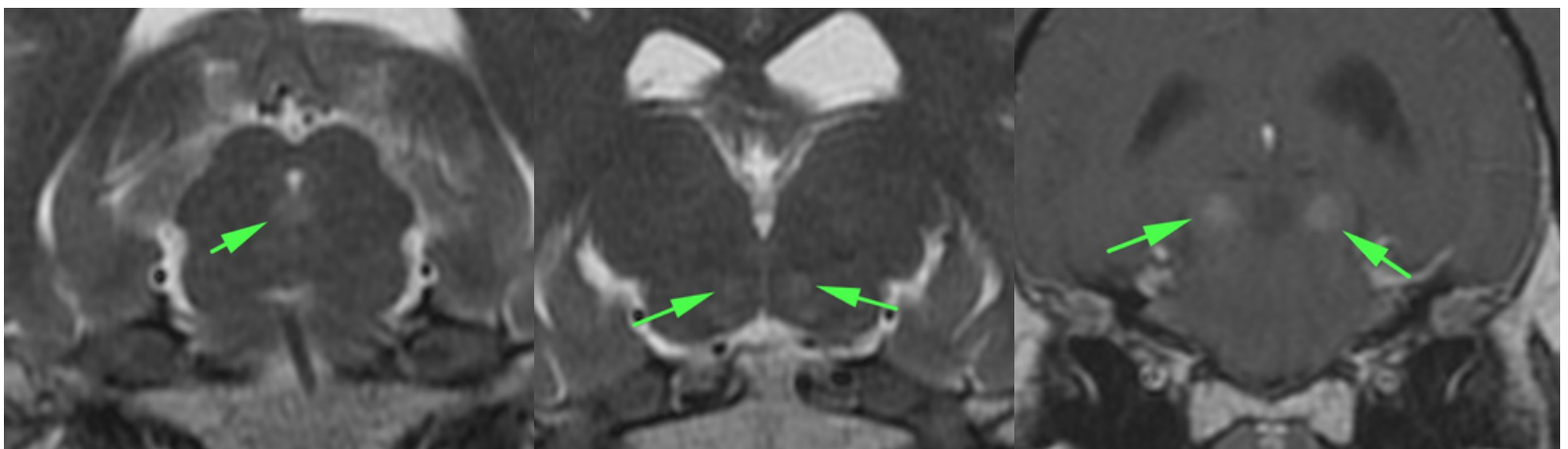


Fig: Note bilaterally symmetrical lesions in the caudal colliculi, vestibular nuclei and cerebellar nodulus



*Note lesions in the para-aqueductal grey matter and thalamus*  
*Enhancement of the caudal colliculi lesions*

**Conclusions:**

- Thiamine deficiency

**Additional comments:**

The presence of bilaterally symmetrical lesions is highly suggestive of a metabolic encephalopathy or toxicoses. The distribution of the lesions in this case is highly suggestive/pathognomonic for thiamine deficiency but definitive diagnosis would require measurement of thiamine levels. Enhancement of lesions in thiamine deficiency is seen sporadically and is not unusual.

If you have any queries regarding this report then please "Add a comment" on the VetCT platform or contact [info@vet-ct.com](mailto:info@vet-ct.com)



Reported by VET.CT

This report is based on the available history and radiographic interpretation only and not on a physical examination of the patient. It has been prepared specifically for interpretation by the currently licensed and registered veterinary surgeon responsible for the care of this patient.

Notes from the comments:

*Hi all!*

*Thank you for your report, and an (unexpected but fixable) answer to the severe rapidly progressive neurological signs in this older boy! I have a quick question for the neurologists, if possible: Patient was started on levetiracetam and received a partial load of phenobarbitone for the seizures he suffered prior to presentation. Now that we are treating his thiamine deficiency and expect his seizures to resolve, at what point do we discontinue the AEDs? Is it ok to discontinue the phenobarbitone and continue the levetiracetam for a bit longer (e.g. 1-2 weeks) until his neurological signs have significantly improved? Or do you recommend suppressing the seizure focus for longer prior to weaning off?*

*Thanks,*

*Client*

Hi,

Thank you very much for contacting VetCT again. My name is [] and I am a Diplomate in Neurology, very nice to meet you! This is a very interesting case. Based on the imaging results I would recommend full bloods (CBC and serum biochemistry with pre- and post-prandial bile acids) to rule out an hepatic encephalopathy, and thiamine levels. It would also be important to ask the owners for possible toxics, the exact diet of the patient (if they cook the food, if they put it in the microwave, which could cause thiamine problems), etc. If the diet is commercial and nothing else is relevant in the history it would be worth letting the food company know about this case, just to make sure it is not a formulation problem.

Regarding the antiepileptic medication I would keep 1 of the drugs for approx. 6 months. If the owners can afford it, or the dog has any liver abnormalities, I would keep the levetiracetam. It is the safest drug and does not have any interaction with the liver. However, it can have "honey-moon effect" and with time is less effective. If in 6 months the animal does not have any seizures, then I would gradually withdraw the medication by 25% every 2-3 weeks.

If the liver is ok and the animal has further seizures, then the phenobarbital is more likely to control the seizures. In that case I would stop the levetiracetam and keep the phenobarbital for 6 months and then gradually withdraw the medication by 25% every 3-4 weeks.

If after stopping the medication the animal suffers further seizures, then antiepileptic drugs lifelong would be recommended. Even if, as you say, this is a "treatable" condition and the most likely is that seizures will stop after this being fixed, there is a chance that the seizures have created an epileptic focus in the brain that could cause further seizures in the future, that is why we recommend to keep the antiepileptic drugs a little bit longer.

Thank you again for contacting VetCT and do not hesitate to contact us if you have any queries

Best wishes,

Neurologist at VetCT

This report/advice is based on the available history and information provided and not on a physical examination of the patient. It must therefore only be interpreted by a currently licensed and registered veterinary surgeon responsible for the care of this patient

*Hi,*

*Thank you so much for your input on this case! After the MRI report came back, we did a little more digging about the commercial diet this dog is fed. 3 months ago, the owners swapped the dog onto this commercial "meatball" diet because the dog had tie-back surgery for laryngeal paralysis, and they were told to feed the dog "meatballs" to decrease risk of aspiration. Interestingly, we found there was a news piece from 2011 about a rottweiler that developed thiamine deficiency after eating this exact diet! It apparently was found to contain excessive levels of sulfur dioxide, which breaks down thiamine and leads to thiamine deficiency.*

*Anyway, I really appreciate your advice on the ongoing AED therapy as well! Hopefully we can bring him back from the brink!*

*Warm regards,*

*Client*



Reported by VET.CT

This report is based on the available history and radiographic interpretation only and not on a physical examination of the patient. It has been prepared specifically for interpretation by the currently licensed and registered veterinary surgeon responsible for the care of this patient.



# Example Reports

## XR



Clinical  
Support  
Services



# Reporting Service: XR

Species: Feline

Breed: Tonkinese

Sex: Male Entire

Age: 3 months

## **Clinical History:**

4 month old male Tonkinese fell off bed this morning and became acutely non-weight bearing.

## **Questions to be answered:**

RHL: confirm slipped capital physis and no other abnormalities, as possible, given stool in colon

LHL: distal to stifle, possible bony changes to tibia and fibula, best seen as a possible step of one region of cortical bone on the frog legged VD; differentials or thoughts?

Number of series / images: 3 / 4

Series: PELVIS DORSO-VENTRAL SMA, PELVIS LATERAL SMA, STIFLE LATERAL

SMA Study dated: 19/Sep/2021

Study received: 19/Sep/2021

Anatomic regions: Pelvis/tail



Reported by VET.CT

This report is based on the available history and radiographic interpretation only and not on a physical examination of the patient. It has been prepared specifically for interpretation by the currently licensed and registered veterinary surgeon responsible for the care of this patient.

Details of study and technical comments: Orthogonal pelvic and lateral pelvic limb radiographs are available for interpretation. The study is diagnostic.

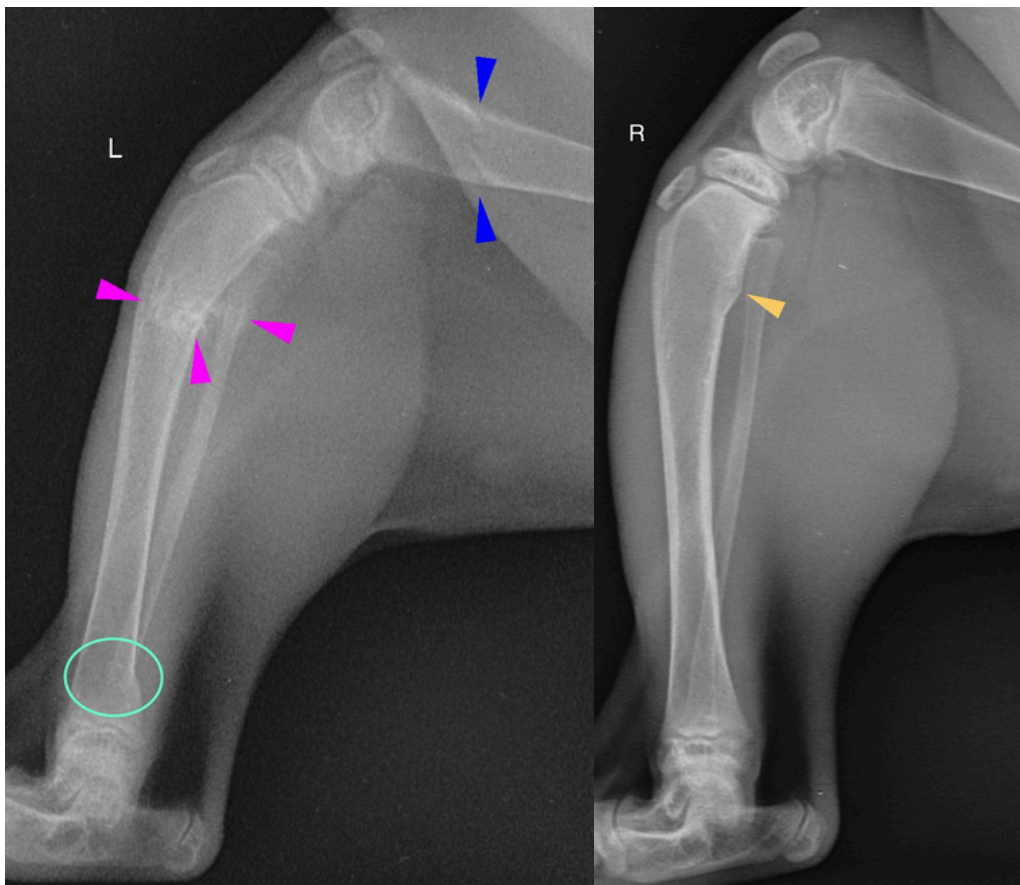
**Diagnostic interpretation:**

The femoral cortices are thin as compared to the tibial cortices. There are oblique folding fractures in the left distal femoral metaphysis (dark blue arrowheads) and left tibial and fibular proximal diaphyses (light pink arrowheads). Faint periosteal proliferation surrounds the fracture margins of the tibial and fibular fracture sites. The distal femoral segment is mildly cranially angulated with cranial angulation of the proximal tibial segment. There is a stair-step like lesion in the left tibial distal diaphyses (light mint circle) in the caudal cortex, as compared to the right.

The right tibial proximal metaphyseal caudal cortex is bulging caudally with smooth increased periosteal proliferation (tan arrowhead).

The left talar ridges are sclerotic and the margins are ill-defined from the distal tibial epiphysis on the lateral image, as compared to the right. The right and left calcanei are lucent within the body, with an ill-defined trabecular pattern and the cortices are thin.

The right hind soft tissues are thicker than the left cranially, however, the right limb is more flexed than the left.



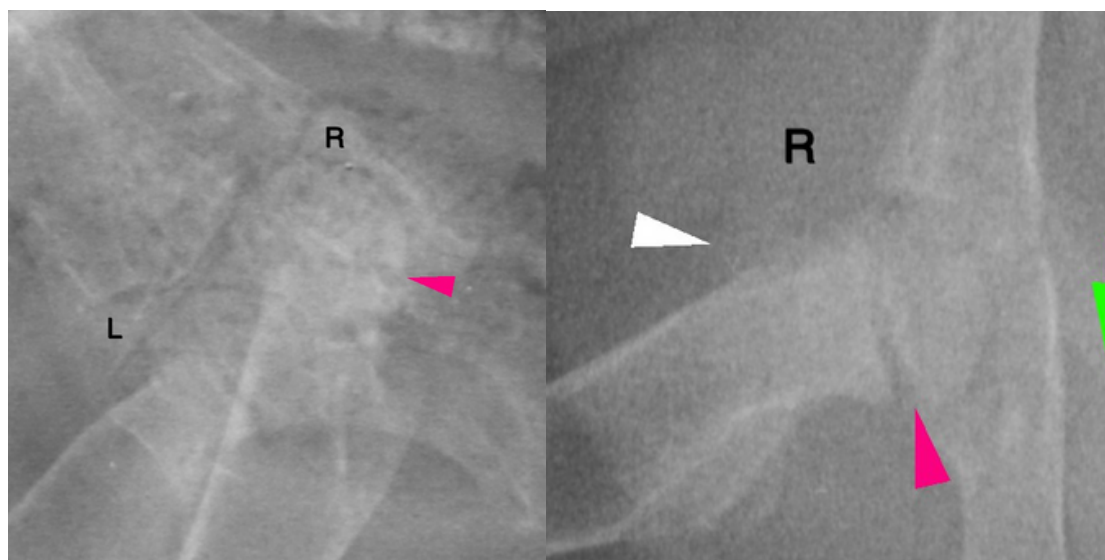
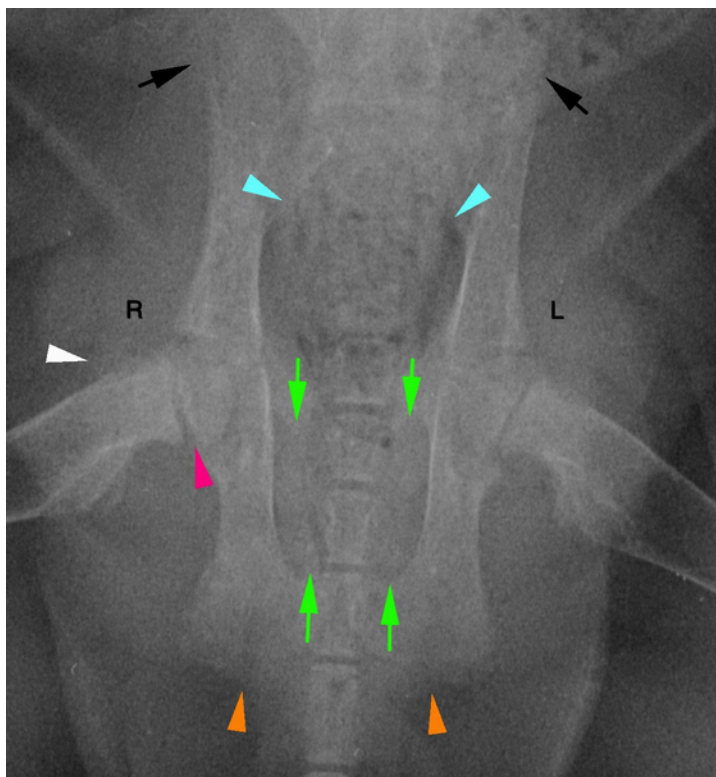
The right proximal femoral physis is wide caudally (pink arrowhead) and narrowed cranially on the VD image. There is mild increased sclerosis of the right femoral neck as compared to the left. Additionally, there is faint,



Reported by VET.CT

This report is based on the available history and radiographic interpretation only and not on a physical examination of the patient. It has been prepared specifically for interpretation by the currently licensed and registered veterinary surgeon responsible for the care of this patient.

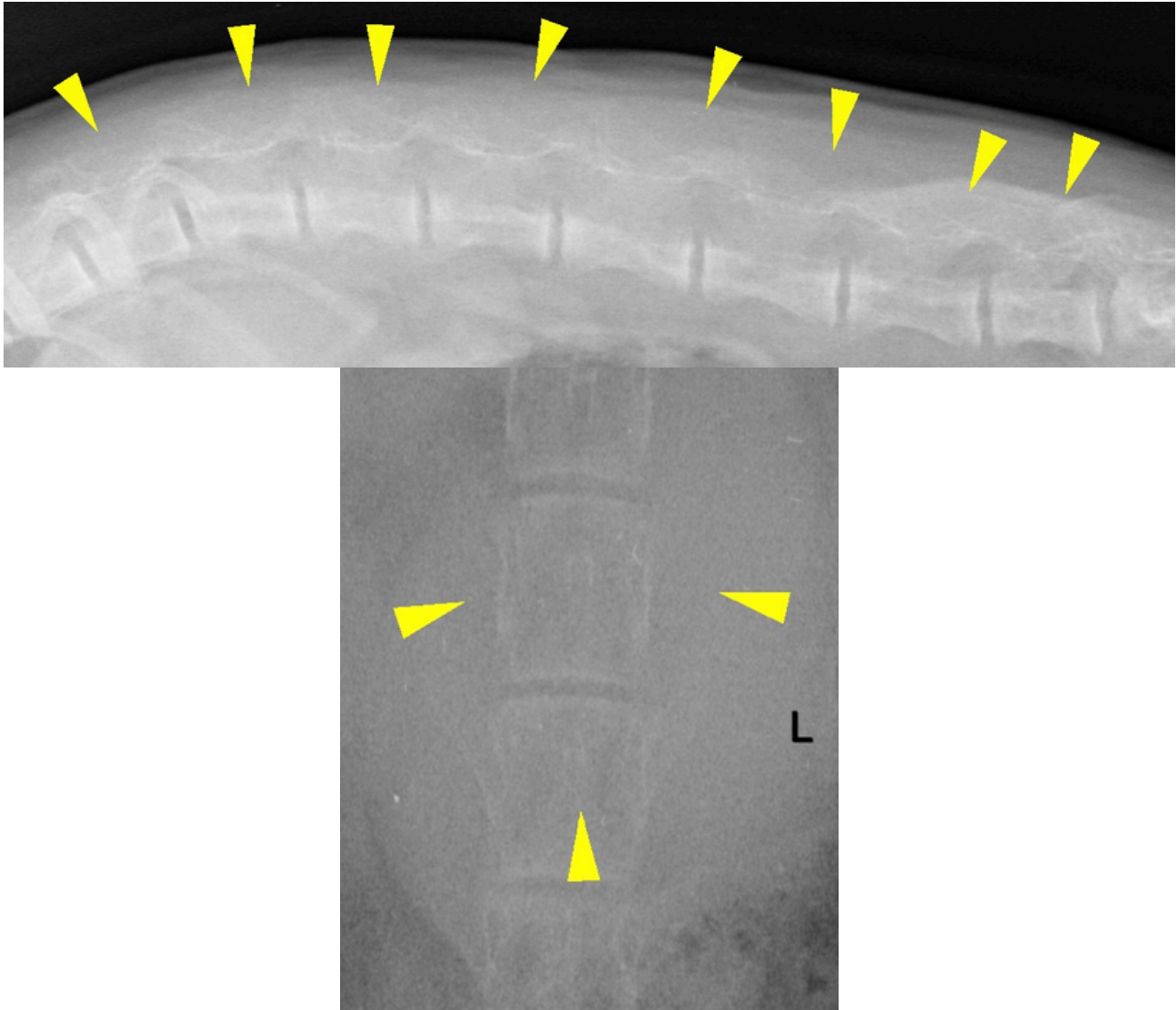
thin osseous formation along the cranial margin of the right femoral neck (white arrowhead). On the lateral image, the right proximal physis is indistinct. Increased soft tissue opacity surrounds the left coxofemoral joint. The pelvic canal (light blue arrowheads) is narrowed caudally, and the obturator foramen (lime green arrows) are obliquely angled, with both lacking the expected round shape. The ilial crests (black arrows) and ischial tuberosities (orange arrowheads) are osteolucent and poorly defined on the VD dorsal image



Reported by VET.CT

This report is based on the available history and radiographic interpretation only and not on a physical examination of the patient. It has been prepared specifically for interpretation by the currently licensed and registered veterinary surgeon responsible for the care of this patient.

The vertebral lamina, pedicles, and articular processes of the caudal thoracic and lumbar vertebra are diffusely osteolucent and ill-defined. On the ventrodorsal image, the lumbar transverse processes are also ill-defined. Yellow arrowheads demark both changes.



The abdominal serosal margin detail is normal with no abnormalities noted. Conclusions:

- Left femoral distal metaphyseal and left tibia/fibular proximal diaphyseal pathological folding fractures
- Wide left proximal femoral physes, likely indicates a capital physal fracture, with regional soft tissue swelling
- Right tibial proximal metaphyseal periosteal proliferation
- Diffuse osteopenia of the lumbar vertebrae and pelvis, with narrowing of the pelvic canal, as described



Reported by VET.CT

This report is based on the available history and radiographic interpretation only and not on a physical examination of the patient. It has been prepared specifically for interpretation by the currently licensed and registered veterinary surgeon responsible for the care of this patient.



**Additional comments:**

The above findings are most consistent with nutritional secondary hyperparathyroidism resulting in osteomalacia from calcium or phosphorus imbalance, (all meat diets). Primary hyperparathyroidism is considered less likely but not excluded. The osseous changes to the right tibia may suggest a prior healing fracture.

An extended leg ventrodorsal image is recommended for evaluation of the right proximal femoral physis to better assess a slipped capital physis. The widened physis does suggest that this is fractured.

Diet changes are recommended. Parathyroid hormone and ionized calcium levels may also be recommended.

If you have any queries regarding this report then please "Add a comment" on the VetCT platform or contact [info@vet-ct.com](mailto:info@vet-ct.com)



**Reported by VET.CT**

This report is based on the available history and radiographic interpretation only and not on a physical examination of the patient. It has been prepared specifically for interpretation by the currently licensed and registered veterinary surgeon responsible for the care of this patient.