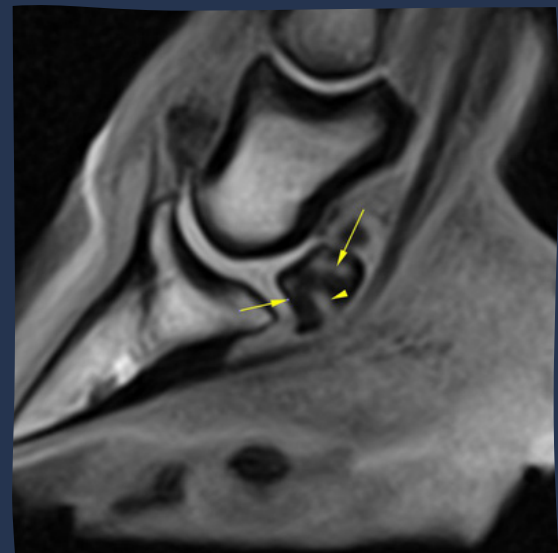
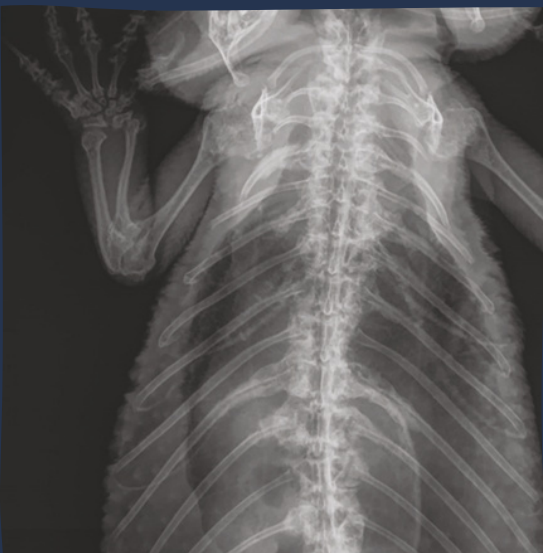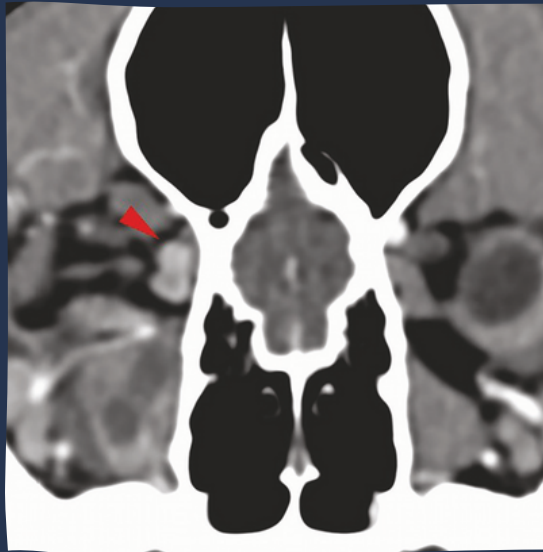




VETCT

Teleradiology | Teleconsulting | Education



TELERADIOLOGY

Expert interpretation of
radiographs, MRI and CT
with annotated images





Reporting Service: CT

Species: Canine

Breed: Border Collie

Sex: Male Entire

Age: 4 months

Clinical History:

4 month old BC puppy that probably had some kind of traumatic incident yesterday evening. Very painful and stiff neck, epistaxis upon arrival, a bit ataxic movement. Cranial nerves ok, proprioception ok. Questions to be answered:

X-rays suspicious of trauma/luxation in the atlanto-axial joint, but very hard to position the puppy good enough for x-rays. Other findings?

Number of series / images: 3 / 1221

Series: TUNNA BONE , IDOSE (3), TUNNA SOFT, IDOSE (3), TUNNA SOFT, IDOSE (4)

Study dated: 01/Oct/2021

Study received: 01/Oct/2021

Anatomic regions: Spine C1 - T2/Neck

Details of study and technical comments: CT study of the cervical vertebral column in bone and soft tissue algorithms pre and post-contrast dated 1st October 2021. Patient in sternal decubitus. The image quality is good.

Diagnostic interpretation:



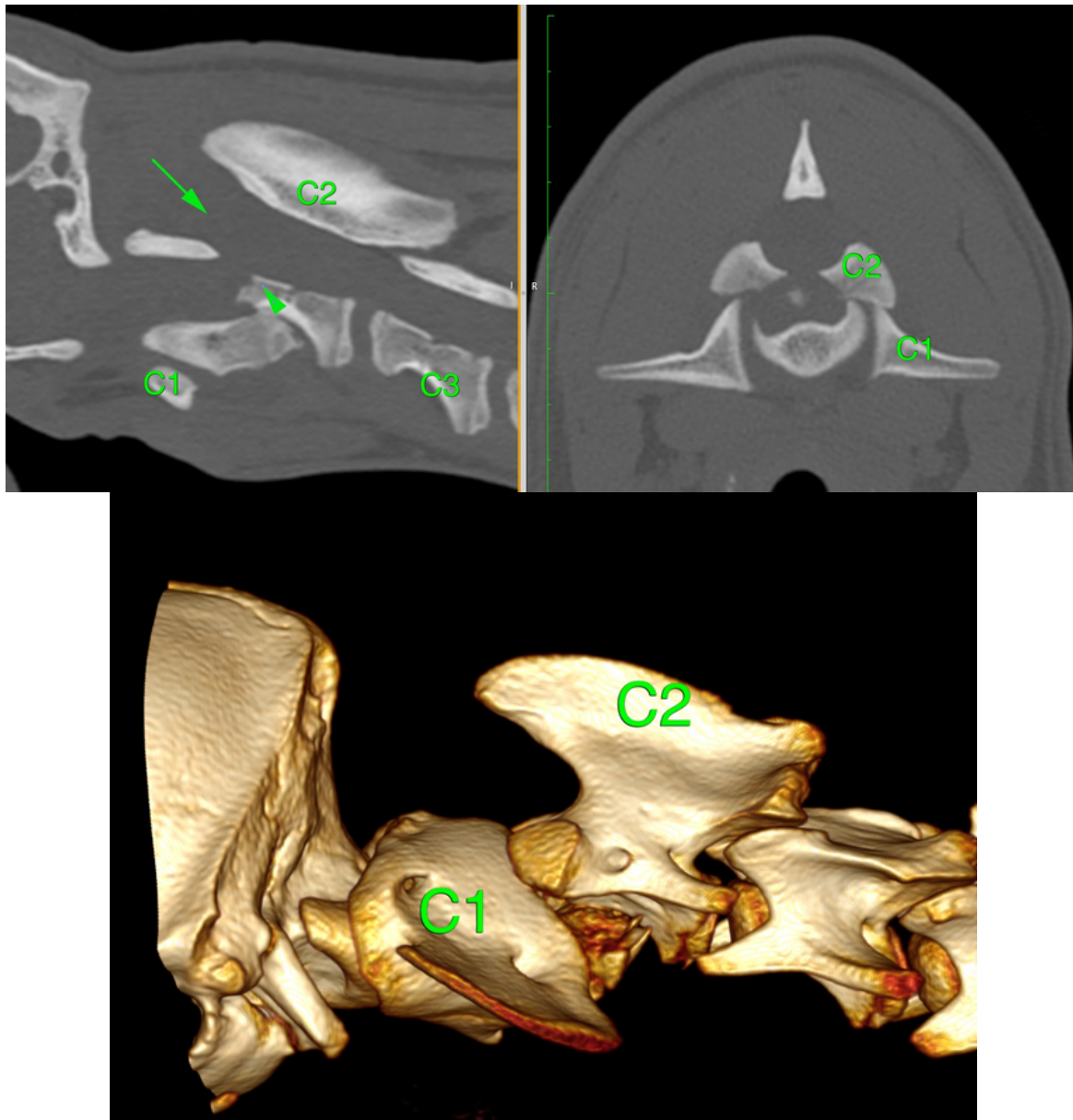
Reported by VetCT

t. +44 (0)1223 422251 www.vet-ct.com e. info@vet-ct.com

Co Number 6955449 Registered Office VetCT, Broers Building, 21 JJ Thomson Avenue, Cambridge, CB3 0FA, United Kingdom
ABN 24601862220 Registered Office in Australia Suite 11, 185-187 High Street Fremantle WA 6160 Australia

This report is based on the available history and radiographic interpretation only and not on a physical examination of the patient. It has been prepared specifically for interpretation by the currently licensed and registered veterinary surgeon responsible for the care of this patient.

There is a complete, displaced, transverse fracture in the mid portion of the body of C2, between the intercentrum 2 and the centrum 2 (green arrowhead). The margins of the fracture are sharp/pointed. The caudal part of the fractured C2 vertebral body is displaced in cranial and dorsal direction inside the vertebral canal, overriding the cranial fragment. Cranially, the fracture involves the ventral surface of the floor of the vertebral canal. Bilaterally, the fracture involves the ventrolateral aspect of the cranial articular surface of C2. The caudal fragment of C2-which contains the neural arch- is luxated in cranial and dorsal direction and overlaps the caudodorsal surface of the arch of C1 (pictures below). There is marked misalignment between the dorsal lamina of C1 and the dorsal lamina of C2. The dens of the axis has normal size, shape, contour, and attenuation. The alignment of the dens related to C1 vertebral foramen is normal with the dog in this position, but there is mild widening of the ventral articular joint space C1-C2. The transverse atlantal ligament looks intact. There is a small focus of mineral attenuation in the ventral atlantooccipital membrane with no additional abnormalities.

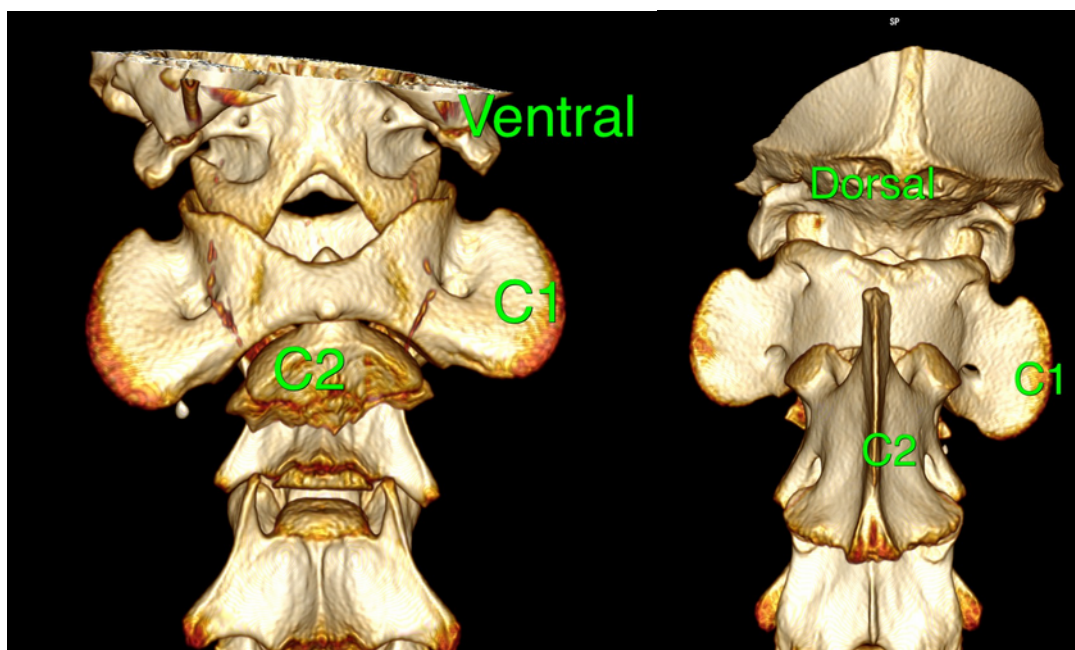


Reported by VetCT

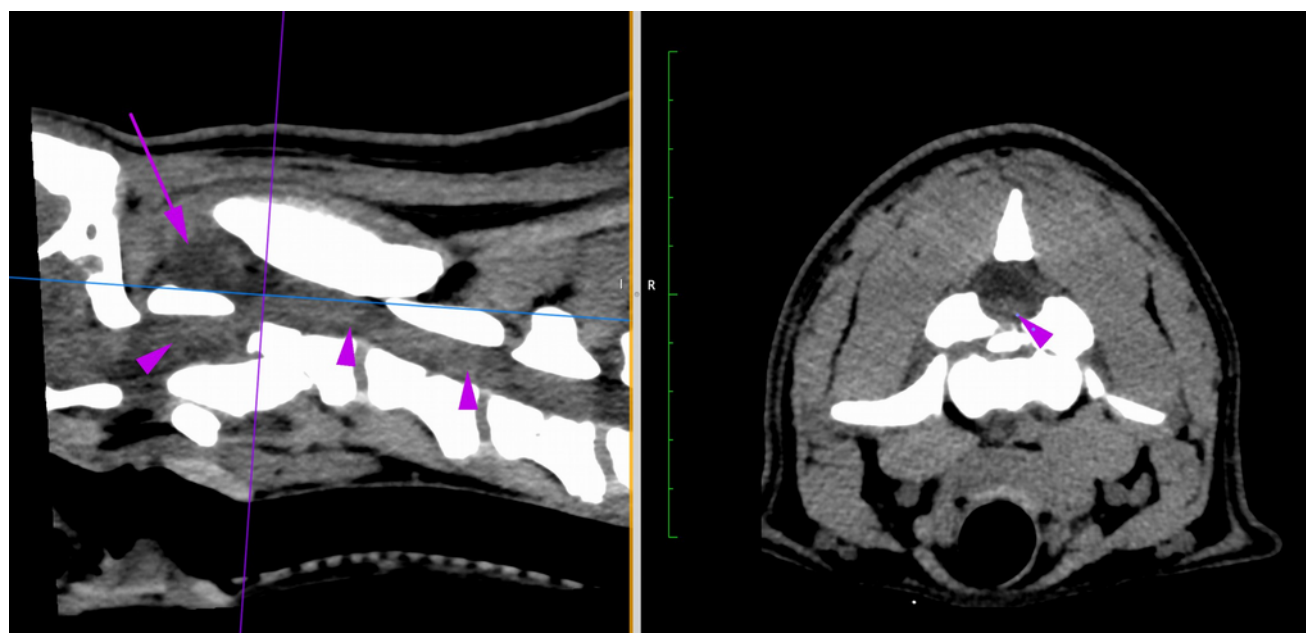
t. +44 (0)1223 422251 www.vet-ct.com e. info@vet-ct.com

Co Number 6955449 Registered Office VetCT, Broers Building, 21 JJ Thomson Avenue, Cambridge, CB3 0FA, United Kingdom
ABN 24601862220 Registered Office in Australia Suite 11, 185-187 High Street Fremantle WA 6160 Australia

This report is based on the available history and radiographic interpretation only and not on a physical examination of the patient. It has been prepared specifically for interpretation by the currently licensed and registered veterinary surgeon responsible for the care of this patient.



As a result of the vertebral fracture and dorsal luxation of C2, there is marked stenosis of the vertebral canal between C1 and C2, with dorsal displacement and compression of the spinal cord (magenta arrowheads). There is widening of the subarachnoid space cranial to the fracture, and the attenuation of the spinal cord is heterogeneous. Caudal to the fracture, the spinal cord looks swollen. There is distension of the C1-C2 joint space with presence of effusion (long magenta arrow).



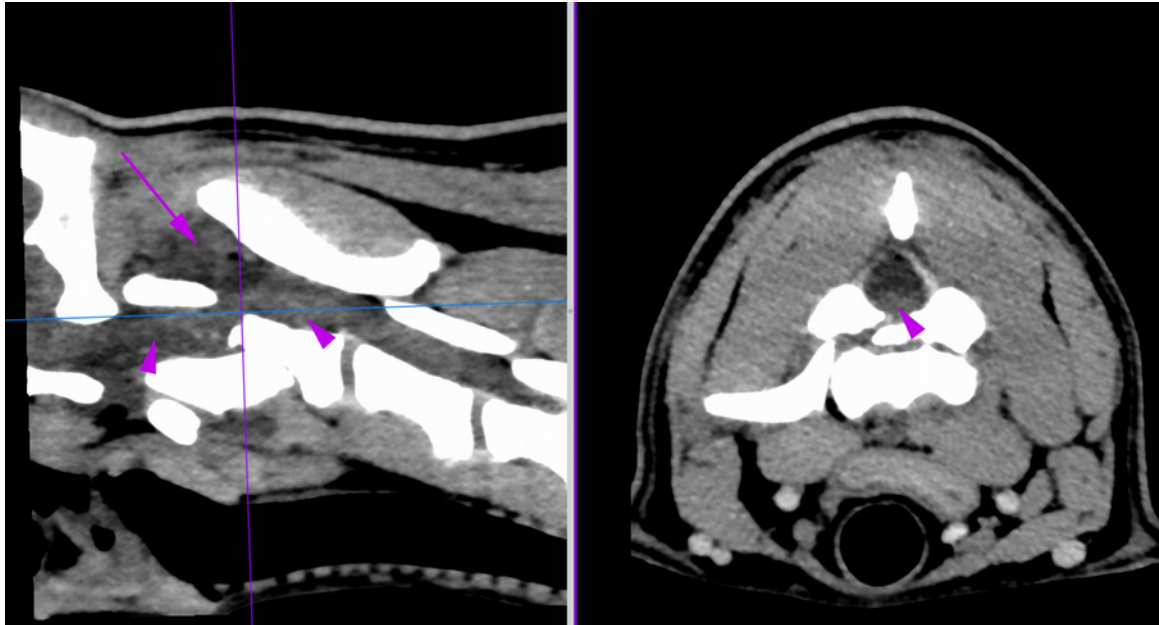
Reported by VetCT

t. +44 (0)1223 422251 www.vet-ct.com e. info@vet-ct.com

Co Number 6955449 Registered Office VetCT, Broers Building, 21 JJ Thomson Avenue, Cambridge, CB3 0FA, United Kingdom

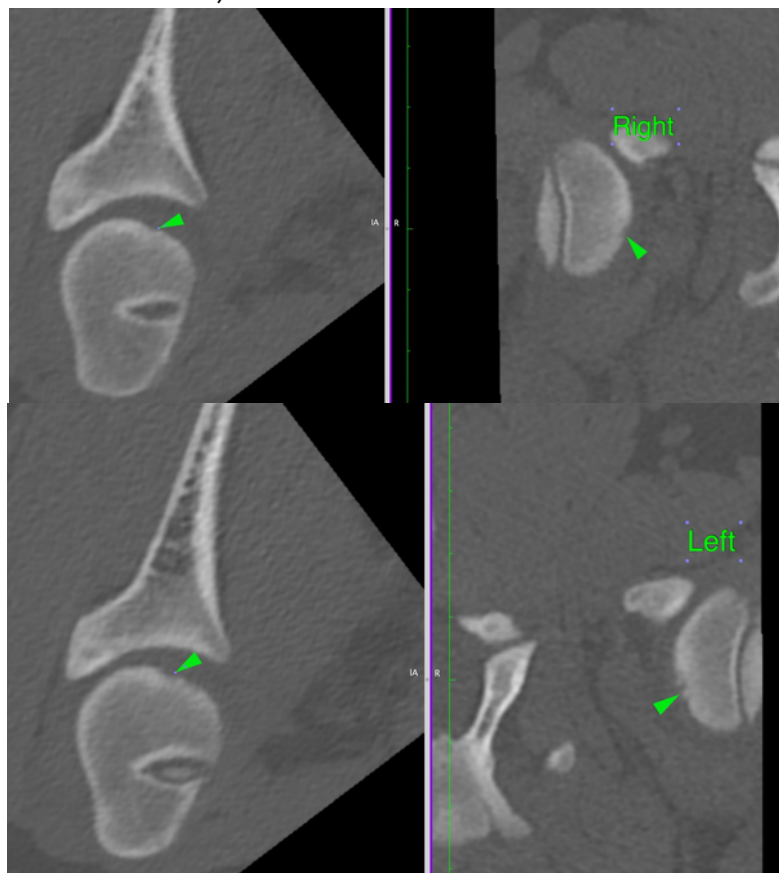
ABN 24601862220 Registered Office in Australia Suite 11, 185-187 High Street Fremantle WA 6160 Australia

This report is based on the available history and radiographic interpretation only and not on a physical examination of the patient. It has been prepared specifically for interpretation by the currently licensed and registered veterinary surgeon responsible for the care of this patient.



There is increased mineral attenuation in the longus capitis muscles ventral to C2 at the fracture site, and presence of fluid attenuation in the facial planes and subcutis. The atlantooccipital joint is normal. No other fractures/fissures are detected in the vertebral column.

There are subtle irregularities in the subchondral bone of the humeral heads bilaterally (arrowheads below) with no additional abnormalities.



Reported by VetCT

t. +44 (0)1223 422251 www.vet-ct.com e. info@vet-ct.com

Co Number 6955449 Registered Office VetCT, Broers Building, 21 JJ Thomson Avenue, Cambridge, CB3 0FA, United Kingdom

ABN 24601862220 Registered Office in Australia Suite 11, 185-187 High Street Fremantle WA 6160 Australia

This report is based on the available history and radiographic interpretation only and not on a physical examination of the patient. It has been prepared specifically for interpretation by the currently licensed and registered veterinary surgeon responsible for the care of this patient.

There are small gas inclusions in the subcutaneous fat of the right dorsolateral cervical region.

Conclusions:

1. Acute, complete, displaced fracture of the mid portion of the vertebral body of C2 with cranial and dorsal luxation of the caudal fragment. Traumatic origin. Non-stable.

a. The fracture involves the ventral surface of the floor of the vertebral canal and the ventral aspect of the cranial articular surface bilaterally.

b. C1-C2 vertebral luxation.

c. Severe stenosis of the vertebral canal at the fracture site with severe spinal cord compression. Spinal cord oedema/contusion is expected. See comments.

d. C1-C2 joint distension/effusion.

e. Changes in the soft tissues of the neck compatible with oedema, inflammation, haematoma.

2. Small irregularities in the surface of the humeral heads: normal (young patient) vs. osteochondrosis.

3. Gas inclusions on the right lateral aspect of the neck: most likely iatrogenic. Open wounds are considered less likely.

Additional comments:

The lesion observed at C2 can explain part of the clinical signs. CT of the head can be considered to exclude additional fractures /trauma that could explain epistaxis or reveal additional lesions in the skull/brain. The status of the spinal cord cannot be completely assessed on CT. MRI would be helpful, if clinically indicated.

If you have any queries regarding this report then please "Add a comment" on the VetCT platform or contact info@vet-ct.com



Reported by VetCT

t. +44 (0)1223 422251 www.vet-ct.com e. info@vet-ct.com

Co Number 6955449 Registered Office VetCT, Broers Building, 21 JJ Thomson Avenue, Cambridge, CB3 0FA, United Kingdom

ABN 24601862220 Registered Office in Australia Suite 11, 185-187 High Street Fremantle WA 6160 Australia

This report is based on the available history and radiographic interpretation only and not on a physical examination of the patient. It has been prepared specifically for interpretation by the currently licensed and registered veterinary surgeon responsible for the care of this patient.



Reporting Service: MRI

Species: Canine Breed: Crossbreed, large Sex: Male Neutered Age: 12 years, 8 months

Clinical History:

-3 episodes of acute onset seizures that started 11/7/21. Diarrhoea in the past 2 days with several bilious vomits and showed HL weakness.

-No known access to toxins.

-Unilateral tieback L arytenoid 04/21.

-PE: Obtunded. Head tilt to L

The drugs that patient had been on prior to the MRI:

1)Mannitol 20% 0.8g/kg IV

2)Dexamethasone 0.2mg/kg IV

3)Levetiracetam 60mg/kg IV

4)Phenobarbitone 6mg/kg IV

5)Maropitant 1mg/kg IV



Reported by VetCT

t. +44 (0)1223 422251 www.vet-ct.com **e.** info@vet-ct.com

Co Number 6955449 Registered Office VetCT, Broers Building, 21 JJ Thomson Avenue, Cambridge, CB3 0FA, United Kingdom
ABN 24601862220 Registered Office in Australia Suite 11, 185-187 High Street Fremantle WA 6160 Australia

This report is based on the available history and radiographic interpretation only and not on a physical examination of the patient. It has been prepared specifically for interpretation by the currently licensed and registered veterinary surgeon responsible for the care of this patient.

6) Ondansetron 0.3mg/kg IV

7) Paracetamol 10mg/kg IV

Number of series / images: 11 / 497

Series: APPARENT DIFFUSION COEFFICIENT (MM²/S), DOR T2, LOCALIZER, SAG T2, TRANS DWI, TRANS T1 FS 3D+C, TRANS T1 SE, TRANS T1 SE C+, TRANS T2, TRANS T2 FLAIR, TRANS T2* GRE SHIM

Study dated: 13/07/2021

Study received: 13/07/2021

Anatomic regions: Head

Details of study and technical comments: MRI of the brain with T2w, FLAIR, T1w (pre and post-contrast images), T2* GRE and DWI sequences. Images are acquired in 3 planes. The images are of excellent quality.

Diagnostic interpretation:

BRAIN: The brain is abnormal in appearance with bilaterally symmetrical focal areas of homogenous T2 hyper-intensity within grey matter involving the caudal colliculi, vestibular nuclei, red nuclei and ventromedially in the thalamus. There are similar lesions in the midline of the ventral para-aqueductal grey matter and the cerebellar nodulus. There is no mass effect or atrophy associated with the lesions. No diffusion abnormalities are visible and there are no hemorrhages on the T2* GRE images. On the T1w images the lesions are iso-mildly hypointense. The post-contrast images show dense, moderate enhancement of the caudal colliculi and vestibular nuclei lesions. No other abnormal enhancement is visible. The conformation of the brain is normal with no gyral or sulcal abnormalities. The rest of the grey and white matter are normal in signal intensity with no signal alterations. The ventricular system is normal in size and shape. There is a normal size and shape to the pituitary gland. No cranial nerve abnormalities are visible. The extra-cranial structures are normal.

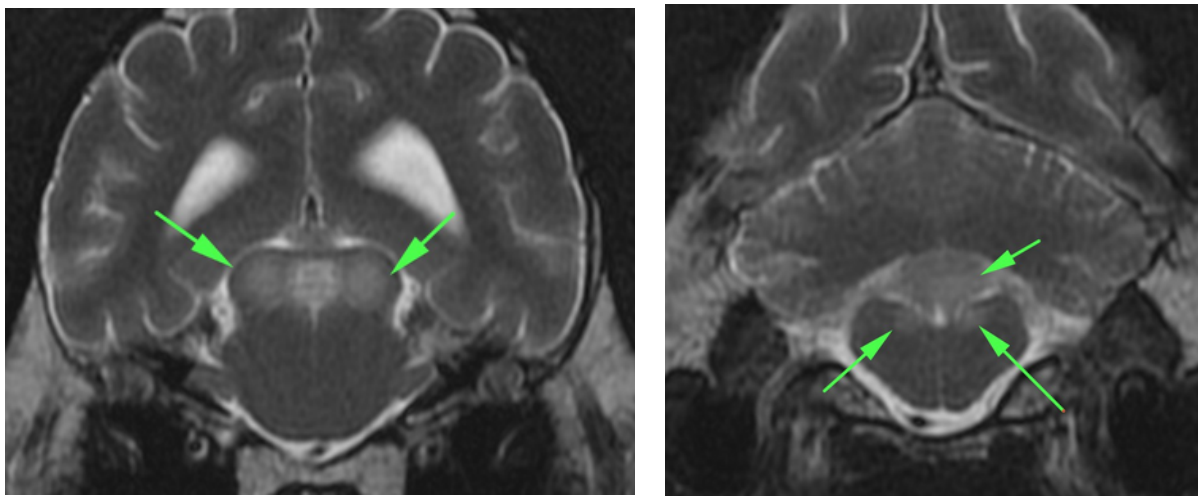
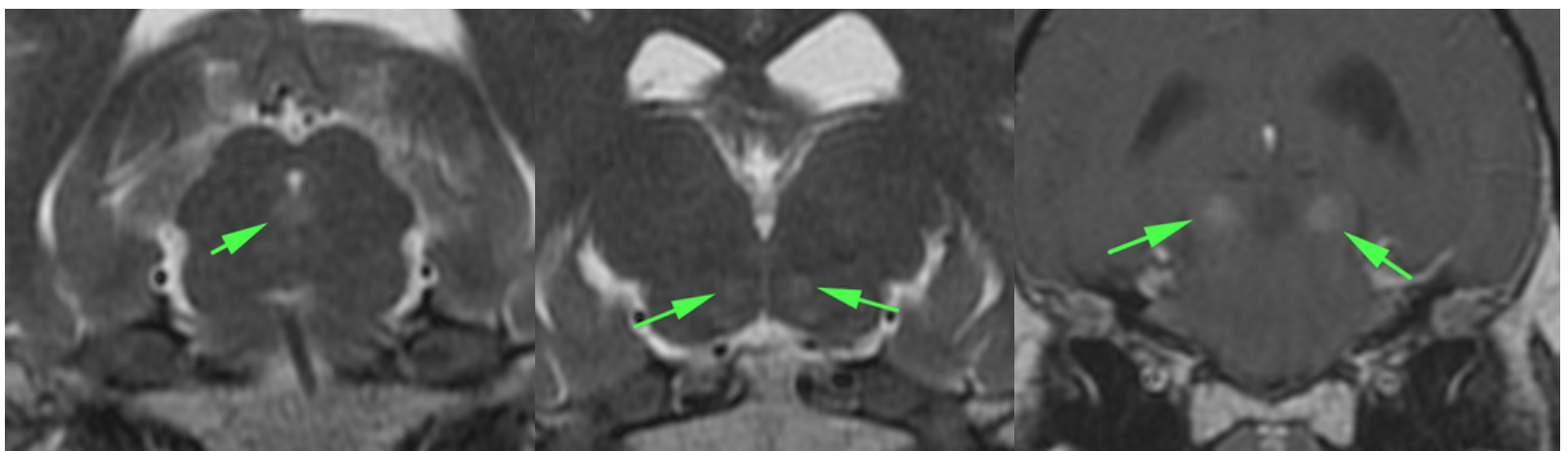


Fig: Note bilaterally symmetrical lesions in the caudal colliculi, vestibular nuclei and cerebellar nodulus



Note lesions in the para-aqueductal grey matter and thalamus
Enhancement of the caudal colliculi lesions

Conclusions:

- Thiamine deficiency

Additional comments:

The presence of bilaterally symmetrical lesions is highly suggestive of a metabolic encephalopathy or toxicoses. The distribution of the lesions in this case is highly suggestive/pathognomonic for thiamine deficiency but definitive diagnosis would require measurement of thiamine levels. Enhancement of lesions in thiamine deficiency is seen sporadically and is not unusual.

If you have any queries regarding this report then please "Add a comment" on the VetCT platform or contact info@vet-ct.com



Reported by VetCT

t. +44 (0)1223 422251 www.vet-ct.com **e.** info@vet-ct.com

Co Number 6955449 Registered Office VetCT, Broers Building, 21 JJ Thomson Avenue, Cambridge, CB3 0FA, United Kingdom

ABN 24601862220 Registered Office in Australia Suite 11, 185-187 High Street Fremantle WA 6160 Australia

This report is based on the available history and radiographic interpretation only and not on a physical examination of the patient. It has been prepared specifically for interpretation by the currently licensed and registered veterinary surgeon responsible for the care of this patient.

Notes from the comments:

Hi all!

Thank you for your report, and an (unexpected but fixable) answer to the severe rapidly progressive neurological signs in this older boy! I have a quick question for the neurologists, if possible: Patient was started on levetiracetam and received a partial load of phenobarbitone for the seizures he suffered prior to presentation. Now that we are treating his thiamine deficiency and expect his seizures to resolve, at what point do we discontinue the AEDs? Is it ok to discontinue the phenobarbitone and continue the levetiracetam for a bit longer (e.g. 1-2 weeks) until his neurological signs have significantly improved? Or do you recommend suppressing the seizure focus for longer prior to weaning off?

Thanks,

Client

Hi,

Thank you very much for contacting VetCT again. My name is [] and I am a Diplomate in Neurology, very nice to meet you! This is a very interesting case. Based on the imaging results I would recommend full bloods (CBC and serum biochemistry with pre- and post-prandial bile acids) to rule out an hepatic encephalopathy, and thiamine levels. It would also be important to ask the owners for possible toxics, the exact diet of the patient (if they cook the food, if they put it in the microwave, which could cause thiamine problems), etc. If the diet is commercial and nothing else is relevant in the history it would be worth letting the food company know about this case, just to make sure it is not a formulation problem. Regarding the antiepileptic medication I would keep 1 of the drugs for approx. 6 months. If the owners can afford it, or the dog has any liver abnormalities, I would keep the levetiracetam. It is the safest drug and does not have any interaction with the liver. However, it can have "honey-moon effect" and with time is less effective. If in 6 months the animal does not have any seizures, then I would gradually withdraw the medication by 25% every 2-3 weeks.

If the liver is ok and the animal has further seizures, then the phenobarbital is more likely to control the seizures. In that case I would stop the levetiracetam and keep the phenobarbital for 6 months and then gradually withdraw the medication by 25% every 3-4 weeks.

If after stopping the medication the animal suffers further seizures, then antiepileptic drugs lifelong would be recommended. Even if, as you say, this is a "treatable" condition and the most likely is that seizures will stop after this being fixed, there is a chance that the seizures have created an epileptic focus in the brain that could cause further seizures in the future, that is why we recommend to keep the antiepileptic drugs a little bit longer.

Thank you again for contacting VetCT and do not hesitate to contact us if you have any queries

Best wishes,

Neurologist at VetCT

This report/advice is based on the available history and information provided and not on a physical examination of the patient. It must therefore only be interpreted by a currently licensed and registered veterinary surgeon responsible for the care of this patient

Hi,

Thank you so much for your input on this case! After the MRI report came back, we did a little more digging about the commercial diet this dog is fed. 3 months ago, the owners swapped the dog onto this commercial "meatball" diet because the dog had tie-back surgery for laryngeal paralysis, and they were told to feed the dog "meatballs" to decrease risk of aspiration. Interestingly, we found there was a news piece from 2011 about a rottweiler that developed thiamine deficiency after eating this exact diet! It apparently was found to contain excessive levels of sulfur dioxide, which breaks down thiamine and leads to thiamine deficiency.

Anyway, I really appreciate your advice on the ongoing AED therapy as well! Hopefully we can bring him back from the brink!

Warm regards,

Client



Reported by VetCT

t. +44 (0)1223 422251 www.vet-ct.com e. info@vet-ct.com

Co Number 6955449 Registered Office VetCT, Broers Building, 21 JJ Thomson Avenue, Cambridge, CB3 0FA, United Kingdom
ABN 24601862220 Registered Office in Australia Suite 11, 185-187 High Street Fremantle WA 6160 Australia

This report is based on the available history and radiographic interpretation only and not on a physical examination of the patient. It has been prepared specifically for interpretation by the currently licensed and registered veterinary surgeon responsible for the care of this patient.



Reporting Service: XR

Species: Feline

Breed: Tonkinese

Sex: Male Entire

Age: 3 months

Clinical History:

4 month old male Tonkinese fell off bed this morning and became acutely non-weight bearing.

Questions to be answered:

RHL: confirm slipped capital physis and no other abnormalities, as possible, given stool in colon

LHL: distal to stifle, possible bony changes to tibia and fibula, best seen as a possible step of one region of cortical bone on the frog legged VD; differentials or thoughts?

Number of series / images: 3 / 4

Series: PELVIS DORSO-VENTRAL SMA, PELVIS LATERAL SMA, STIFLE LATERAL

SMA Study dated: 19/Sep/2021

Study received: 19/Sep/2021

Anatomic regions: Pelvis/tail



Reported by VetCT

t. +44 (0)1223 422251 www.vet-ct.com e. info@vet-ct.com

Co Number 6955449 Registered Office VetCT, Broers Building, 21 JJ Thomson Avenue, Cambridge, CB3 0FA, United Kingdom

ABN 24601862220 Registered Office in Australia Suite 11, 185-187 High Street Fremantle WA 6160 Australia

This report is based on the available history and radiographic interpretation only and not on a physical examination of the patient. It has been prepared specifically for interpretation by the currently licensed and registered veterinary surgeon responsible for the care of this patient.

Details of study and technical comments: Orthogonal pelvic and lateral pelvic limb radiographs are available for interpretation. The study is diagnostic.

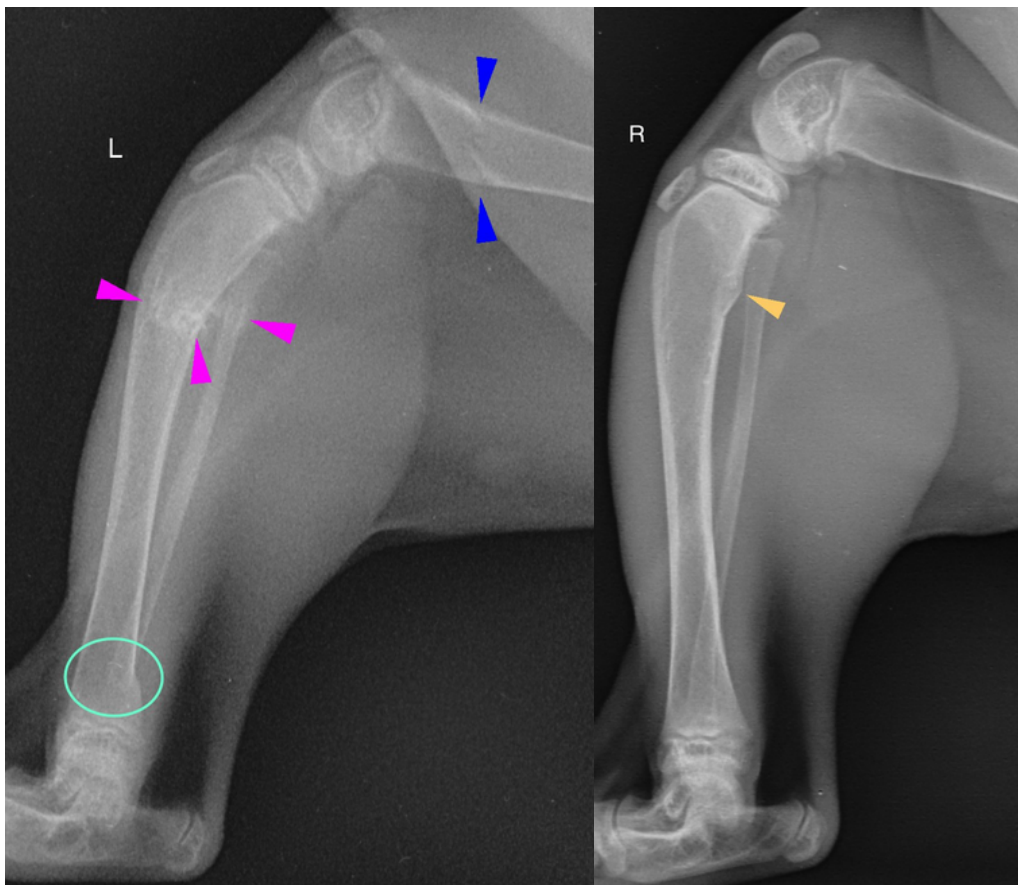
Diagnostic interpretation:

The femoral cortices are thin as compared to the tibial cortices. There are oblique folding fractures in the left distal femoral metaphysis (dark blue arrowheads) and left tibial and fibular proximal diaphyses (light pink arrowheads). Faint periosteal proliferation surrounds the fracture margins of the tibial and fibular fracture sites. The distal femoral segment is mildly cranially angulated with cranial angulation of the proximal tibial segment. There is a stair-step like lesion in the left tibial distal diaphyses (light mint circle) in the caudal cortex, as compared to the right.

The right tibial proximal metaphyseal caudal cortex is bulging caudally with smooth increased periosteal proliferation (tan arrowhead).

The left talar ridges are sclerotic and the margins are ill-defined from the distal tibial epiphysis on the lateral image, as compared to the right. The right and left calcanei are lucent within the body, with an ill-defined trabecular pattern and the cortices are thin.

The right hind soft tissues are thicker than the left cranially, however, the right limb is more flexed than the left.



The right proximal femoral physis is wide caudally (pink arrowhead) and narrowed cranially on the VD image. There is mild increased sclerosis of the right femoral neck as compared to the left. Additionally, there is faint,



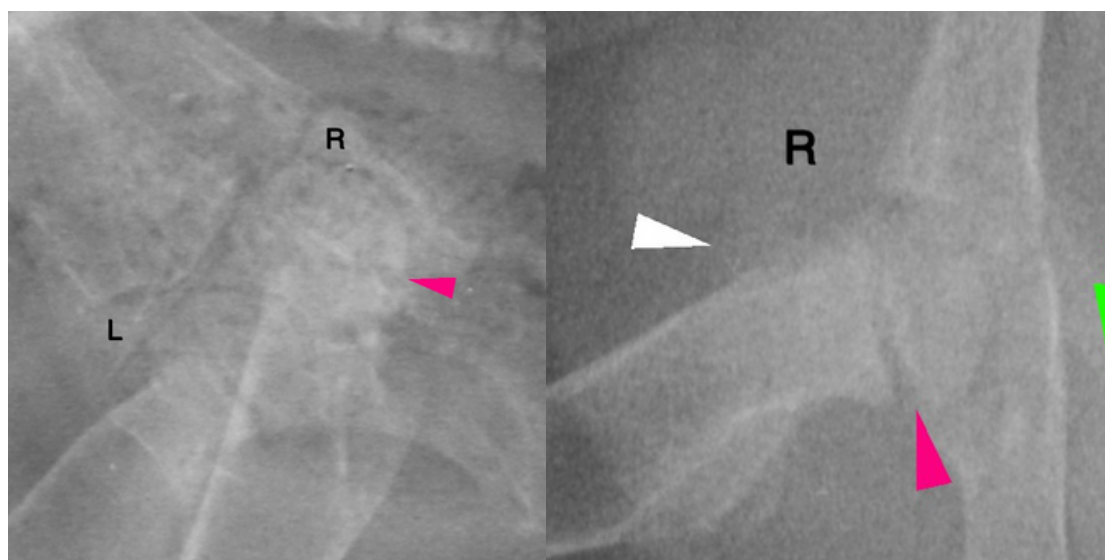
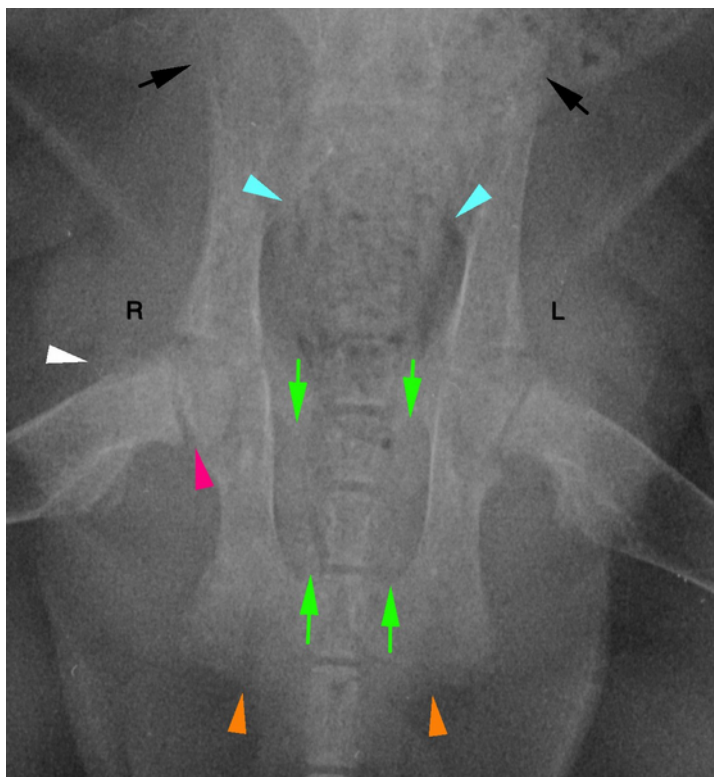
Reported by VetCT

t. +44 (0)1223 422251 www.vet-ct.com e. info@vet-ct.com

Co Number 6955449 Registered Office VetCT, Broers Building, 21 JJ Thomson Avenue, Cambridge, CB3 0FA, United Kingdom
ABN 24601862220 Registered Office in Australia Suite 11, 185-187 High Street Fremantle WA 6160 Australia

This report is based on the available history and radiographic interpretation only and not on a physical examination of the patient. It has been prepared specifically for interpretation by the currently licensed and registered veterinary surgeon responsible for the care of this patient.

thin osseous formation along the cranial margin of the right femoral neck (white arrowhead). On the lateral image, the right proximal physis is indistinct. Increased soft tissue opacity surrounds the left coxofemoral joint. The pelvic canal (light blue arrowheads) is narrowed caudally, and the obturator foramen (lime green arrows) are obliquely angled, with both lacking the expected round shape. The ilial crests (black arrows) and ischial tuberosities (orange arrowheads) are osteoluculent and poorly defined on the VD dorsal image



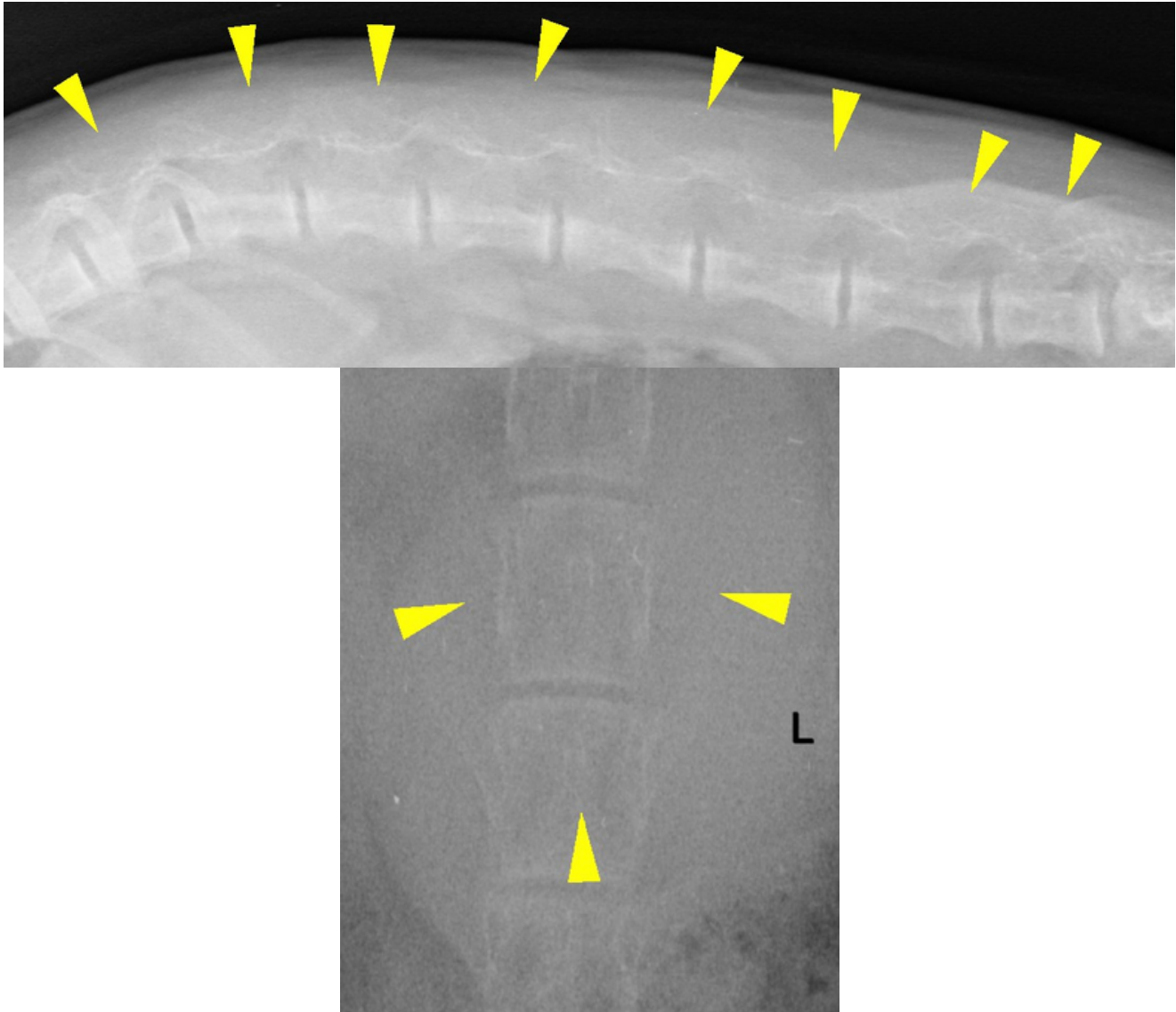
Reported by VetCT

t. +44 (0)1223 422251 www.vet-ct.com e. info@vet-ct.com

Co Number 6955449 Registered Office VetCT, Broers Building, 21 JJ Thomson Avenue, Cambridge, CB3 0FA, United Kingdom
ABN 24601862220 Registered Office in Australia Suite 11, 185-187 High Street Fremantle WA 6160 Australia

This report is based on the available history and radiographic interpretation only and not on a physical examination of the patient. It has been prepared specifically for interpretation by the currently licensed and registered veterinary surgeon responsible for the care of this patient.

The vertebral lamina, pedicles, and articular processes of the caudal thoracic and lumbar vertebra are diffusely osteolucent and ill-defined. On the ventrodorsal image, the lumbar transverse processes are also ill-defined. Yellow arrowheads demark both changes.



The abdominal serosal margin detail is normal with no abnormalities noted. Conclusions:

- Left femoral distal metaphyseal and left tibia/fibular proximal diaphyseal pathological folding fractures
- Wide left proximal femoral physes, likely indicates a capital physal fracture, with regional soft tissue swelling
- Right tibial proximal metaphyseal periosteal proliferation
- Diffuse osteopenia of the lumbar vertebrae and pelvis, with narrowing of the pelvic canal, as described



Reported by VetCT

t. +44 (0)1223 422251 **www.vet-ct.com** **e.** info@vet-ct.com

Co Number 6955449 Registered Office VetCT, Broers Building, 21 JJ Thomson Avenue, Cambridge, CB3 0FA, United Kingdom

ABN 24601862220 Registered Office in Australia Suite 11, 185-187 High Street Fremantle WA 6160 Australia

This report is based on the available history and radiographic interpretation only and not on a physical examination of the patient. It has been prepared specifically for interpretation by the currently licensed and registered veterinary surgeon responsible for the care of this patient.

Additional comments:

The above findings are most consistent with nutritional secondary hyperparathyroidism resulting in osteomalacia from calcium or phosphorus imbalance, (all meat diets). Primary hyperparathyroidism is considered less likely but not excluded. The osseous changes to the right tibia may suggest a prior healing fracture.

An extended leg ventrodorsal image is recommended for evaluation of the right proximal femoral physis to better assess a slipped capital physis. The widened physis does suggest that this is fractured.

Diet changes are recommended. Parathyroid hormone and ionized calcium levels may also be recommended.

If you have any queries regarding this report then please "Add a comment" on the VetCT platform or contact info@vet-ct.com



Reported by VetCT

t. +44 (0)1223 422251 www.vet-ct.com **e.** info@vet-ct.com

Co Number 6955449 Registered Office VetCT, Broers Building, 21 JJ Thomson Avenue, Cambridge, CB3 0FA, United Kingdom
ABN 24601862220 Registered Office in Australia Suite 11, 185-187 High Street Fremantle WA 6160 Australia

This report is based on the available history and radiographic interpretation only and not on a physical examination of the patient. It has been prepared specifically for interpretation by the currently licensed and registered veterinary surgeon responsible for the care of this patient.



Reporting Service: CT

Species: Reptile/Amphibian Breed: Tortoise/Turtle Sex: Female Entire Age: 5 years

Clinical History:

Diarrhoea and vomiting. Bloods: high AST, CK

Questions to be answered:

What is the cause of the vomiting/diarrhoea?

Any signs of liver problems?

Number of series / images: 3 / 4400

Series: 2.0, BODY 0.5, BONE 0.5

Study dated: 07/04/2021

Study received: 07/04/2021

Anatomic regions: Thorax, Head, Abdomen

Details of study and technical comments: A full-body CT study of a turtle is available for interpretation. The study consists of pre- and postcontrast series processed with high and low-frequency reconstruction algorithms. The study is of excellent diagnostic quality.



Reported by VetCT

t. +44 (0)1223 422251 **www.vet-ct.com** **e.** info@vet-ct.com

Co Number 6955449 Registered Office VetCT, Broers Building, 21 JJ Thomson Avenue, Cambridge, CB3 0FA, United Kingdom

ABN 24601862220 Registered Office in Australia Suite 11, 185-187 High Street Fremantle WA 6160 Australia

This report is based on the available history and radiographic interpretation only and not on a physical examination of the patient. It has been prepared specifically for interpretation by the currently licensed and registered veterinary surgeon responsible for the care of this patient.

Diagnostic interpretation: HEAD

The nasal cavities are symmetrically gas-filled. The nasopharynx is unremarkable. The position of the globes is symmetric, and the globes are normal in size and shape. The middle ear cavities are gas-filled. There are no intracranial abnormalities noted.

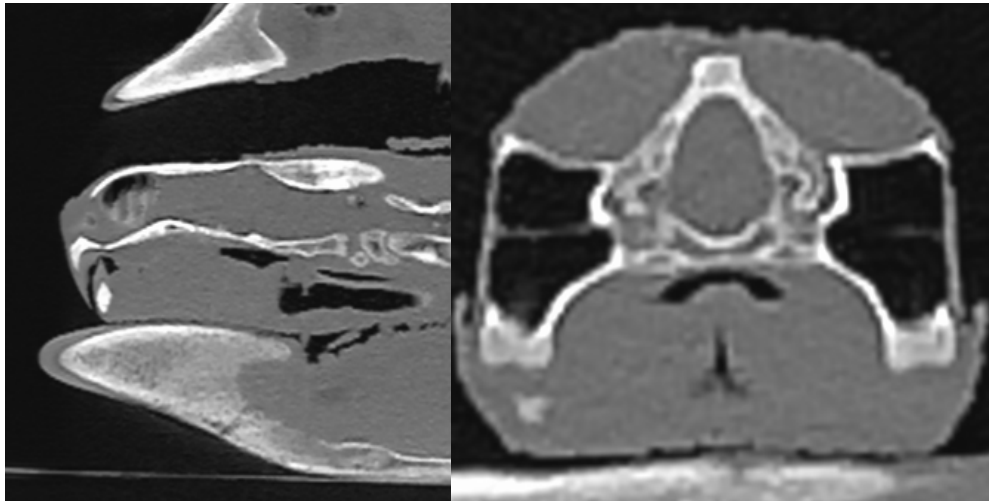


Figure 1. Sagittal and transverse images of the head documenting its normal appearance.

COELOM

The trachea and main stem bronchi are uniformly gas-filled. The lungs occupy maximally $\frac{1}{2}$ of the height of the coelom and are unremarkable.

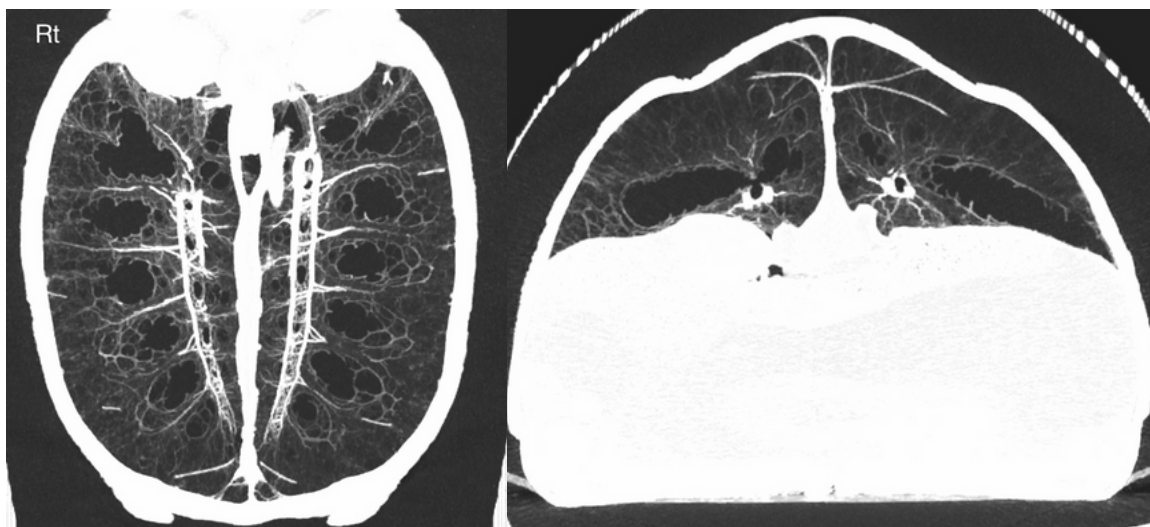

Figure 2. Dorsal and transverse thick-slab, maximum intensity projection images of the coelom demonstrating normal architecture and vascularisation of the lungs.

The thyroid gland cannot be well delineated the cardiovascular structures are unremarkable. The liver is normal in size and shape; it is diffusely hypoattenuating in the precontrast study (HU=7) and shows a heterogeneous contrast enhancement. The walls of the gallbladder are thick and show a strong contrast enhancement; a minimal amount of bile is noted within its lumen.



Reported by VetCT

t. +44 (0)1223 422251 www.vet-ct.com e. info@vet-ct.com

Co Number 6955449 Registered Office VetCT, Broers Building, 21 JJ Thomson Avenue, Cambridge, CB3 0FA, United Kingdom

ABN 24601862220 Registered Office in Australia Suite 11, 185-187 High Street Fremantle WA 6160 Australia

This report is based on the available history and radiographic interpretation only and not on a physical examination of the patient. It has been prepared specifically for interpretation by the currently licensed and registered veterinary surgeon responsible for the care of this patient.

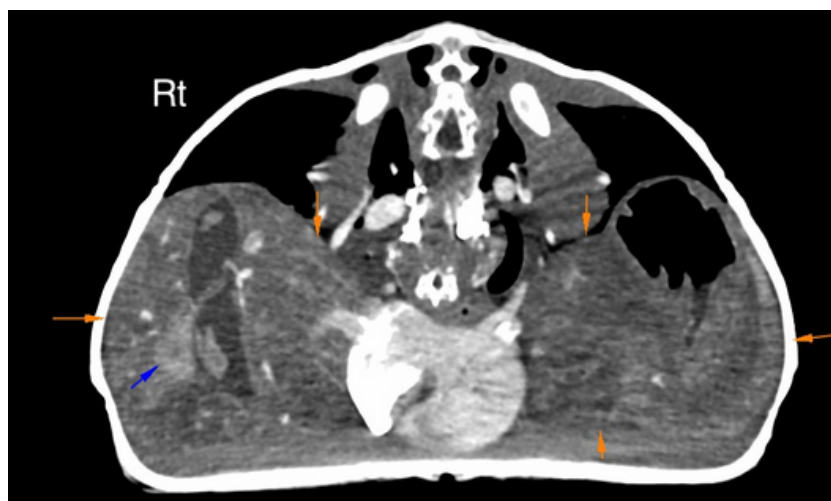

Figure 3. Transverse postcontrast image of the coelom. The orange arrows indicate the liver, which is heterogeneous. The blue arrow points at the gallbladder; please note its thick walls.

The spleen is homogeneous soft-tissue attenuating; it measures approximately (CrCd x ML x DV = 3.4 cm x 3.8 cm x 2.7 cm).

Caudally to the liver, there is a large accumulation of fluid attenuating material. It seems to be well defined and causes a dorsal displacement of the intestines. However, in its most cranial aspect, in the midline, a very thin, soft tissue attenuating structure crosses it. Moreover, there is a small amount of fluid between the coelomic wall and the liver, between the segments of the right division of the liver and between the stomach and left part of the liver.

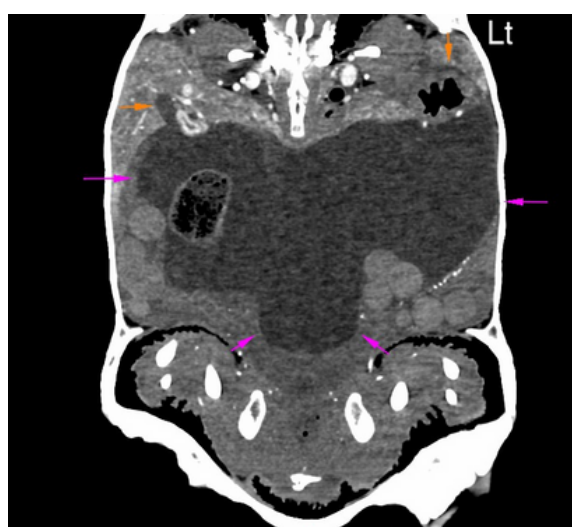


Figure 4. Dorsal postcontrast image of the coelom. The pink arrows indicate coelomic fluid, which seems to be well defined. The orange arrows indicate fluid between the segments of the liver and the liver and stomach.

Multiple, differently sized (up to 2.4 cm), homogeneous, soft tissue attenuating follicles are noted in the left and right caudal aspect of the coelom; few have a hypoattenuating peripheral rim. The kidneys are bilaterally symmetric, normal in size and shape, and they show mildly heterogeneous contrast enhancement.



Reported by VetCT

t. +44 (0)1223 422251 www.vet-ct.com e. info@vet-ct.com

Co Number 6955449 Registered Office VetCT, Broers Building, 21 JJ Thomson Avenue, Cambridge, CB3 0FA, United Kingdom
ABN 24601862220 Registered Office in Australia Suite 11, 185-187 High Street Fremantle WA 6160 Australia

This report is based on the available history and radiographic interpretation only and not on a physical examination of the patient. It has been prepared specifically for interpretation by the currently licensed and registered veterinary surgeon responsible for the care of this patient.

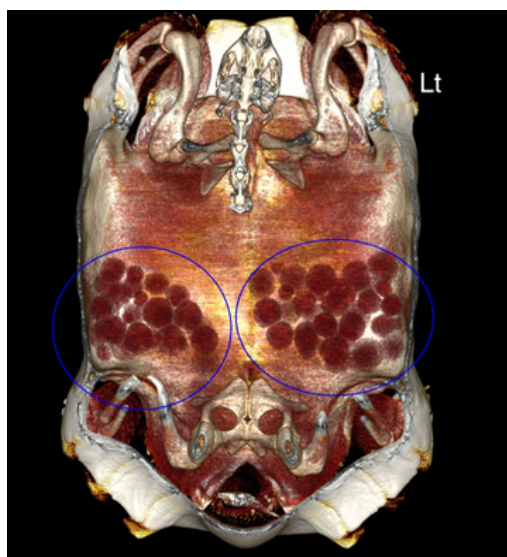


Figure 5. Dorsal volume-rendered image of the coelom with removed dorsal part of the carapace. The blue circles indicate ovarian follicles.

The stomach contains a small amount of gas and mixed gas and soft tissue attenuating material. The duodenum contains a small amount of fluid; its wall is focally thickened. The small intestines are mostly empty. The colon contains a moderate amount of formed faecal material.

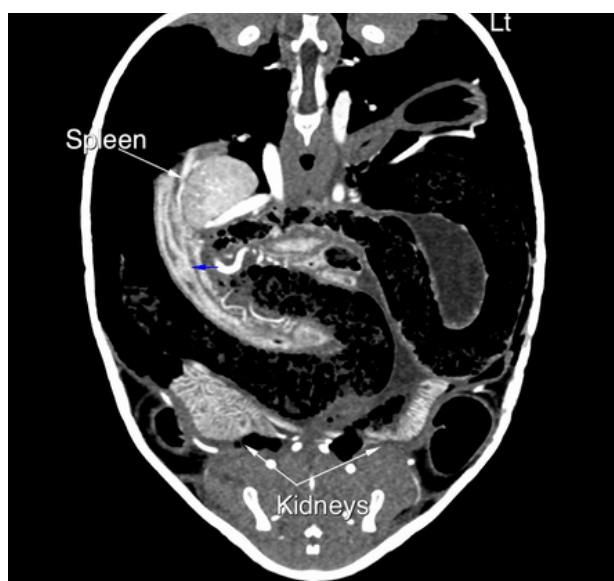


Figure 6. Dorsal image of the coelom. The blue arrow points at the focally thickened wall of the duodenum.

Conclusions:

1. Moderate generalised hepatopathy.
 - a. Cholecystitis is possible.
2. Multiple ovarian follicles. Follicular stasis cannot be ruled out.
3. Suspicion of a focal mural lesion of the duodenum.

Large amount of fluid in the coelom. It represents most likely a combination of the distended urinary bladder and mild coelomic effusion. Severe coelomic effusion cannot be ruled out but is considered much less likely.

4. Hypothyroidism is possible.



Reported by VetCT

t. +44 (0)1223 422251 **www.vet-ct.com** **e.** info@vet-ct.com

Co Number 6955449 Registered Office VetCT, Broers Building, 21 JJ Thomson Avenue, Cambridge, CB3 0FA, United Kingdom

ABN 24601862220 Registered Office in Australia Suite 11, 185-187 High Street Fremantle WA 6160 Australia

This report is based on the available history and radiographic interpretation only and not on a physical examination of the patient. It has been prepared specifically for interpretation by the currently licensed and registered veterinary surgeon responsible for the care of this patient.

Additional comments:

The diffuse decreased attenuation of the liver may be physiologic due to vitellogenesis or due to hepatic lipidosis. The heterogeneous contrast enhancement may be due to the very early phase of the post-contrast study. Hepatitis or much less likely diffuse hepatic neoplasia cannot be ruled out. The clinical significance of the focal mural thickening of the duodenum is unclear; it might be artefactual due to the folding of the mucosa. A true mural lesion (inflammatory, hyperplastic, or less likely neoplastic) is possible.

If it is clinically indicated, an ultrasound of the coelom could be considered to assess further the coelomic effusion and to distinguish it from the distended urinary bladder. Serial monitoring of the ovarian follicles can help to distinguish between the physiologic follicular atresia/resorption and follicular stasis.

If you have any queries regarding this report then please "Add a comment" on the VetCT platform or contact info@vet-ct.com



Reported by VetCT

t. +44 (0)1223 422251 www.vet-ct.com **e.** info@vet-ct.com

Co Number 6955449 Registered Office VetCT, Broers Building, 21 JJ Thomson Avenue, Cambridge, CB3 0FA, United Kingdom
ABN 24601862220 Registered Office in Australia Suite 11, 185-187 High Street Fremantle WA 6160 Australia

This report is based on the available history and radiographic interpretation only and not on a physical examination of the patient. It has been prepared specifically for interpretation by the currently licensed and registered veterinary surgeon responsible for the care of this patient.



Reporting Service: MRI

Species: Equine

Breed: Crossbreed

Sex: Mare

Age: 14 years, 9 months

Clinical History:

3/5 lame LF for 4 weeks. Blocks to PD. Doesn't switch. NAD on rads.

Questions to be answered:

Number of series / images: 31 / 490

Series: L_FORE_FOOT / PILOT, L_FORE_FOOT / PILOT OF A PILOT, L_FORE_FOOT / STIR FSE PTR, L_FORE_FOOT / STIR FSE SAG/+, L_FORE_FOOT / STIR TEST, L_FORE_FOOT / T1W 3D DTRA, L_FORE_FOOT / T1W 3D FRO, L_FORE_FOOT / T1W 3D PTR, L_FORE_FOOT / T1W 3D SAG, L_FORE_FOOT / T1W 3D TRA, L_FORE_FOOT / T2*W 3D FRO, L_FORE_FOOT / T2*W 3D SAG, L_FORE_FOOT / T2W FSE DTRA, L_FORE_FOOT / T2W FSE FTRA, L_FORE_FOOT / T2W FSE PTR

Study dated: 05/Oct/2021

Study received: 05/Oct/2021

Anatomic regions: Front foot/ pastern - Left, Front foot/ pastern - Right



Reported by VetCT

t. +44 (0)1223 422251 www.vet-ct.com e. info@vet-ct.com

Co Number 6955449 Registered Office VetCT, Broers Building, 21 JJ Thomson Avenue, Cambridge, CB3 0FA, United Kingdom
ABN 24601862220 Registered Office in Australia Suite 11, 185-187 High Street Fremantle WA 6160 Australia

This report is based on the available history and radiographic interpretation only and not on a physical examination of the patient. It has been prepared specifically for interpretation by the currently licensed and registered veterinary surgeon responsible for the care of this patient.

Details of study and technical comments: MRI examination of the front feet. Images are of good diagnostic quality.

Diagnostic interpretation:

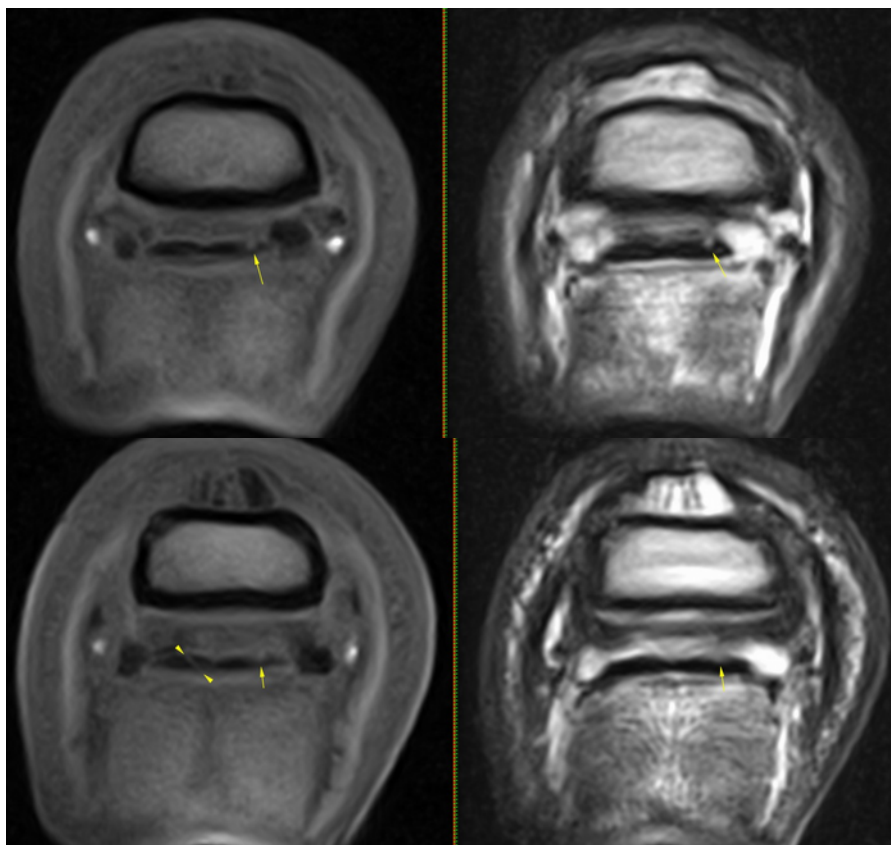
Left foot:

There is moderate effusion of the navicular bursa causing dorsal and slightly distal displacement of the collateral sesamoidean ligaments. The collateral sesamoidean ligaments are subjectively thick but symmetrical in size and with normal signal intensity.

A lesion is seen in the abaxial aspect of the lateral lobe of the deep digital flexor tendon in the presesamoidean region. The lesion has the characteristics of a dorsal core lesion and has increased signal intensity in all sequences. There is disruption of the dorsal border of the lobe at the level of the lesion.

The lesion is not seen palmar to the navicular bone although subtle increased STIR signal intensity is seen in the palmar compact bone of the navicular bone laterally. In the medial lobe, a parasagittal split is present at the same level but visible in T1W sequences only. It continues palmar to the navicular bone. At the tendon insertion a small core lesion is seen in the medial lobe in T1W sequences; the lesion is faintly visible in T2W FSE but not in STIR sequences. There is mild increased STIR signal intensity in the medial portion of the flexor surface of the distal phalanx.

The medial collateral ligament of the distal interphalangeal joint is mildly heterogeneous in T2W FSE sequences in the axial aspect of the body. The ligament is mildly enlarged but this maybe related to foot positioning during image acquisition.



Transverse T1W GRE and T2W FSE sequences showing the active lesion in the lateral lobe (arrows) and the chronic lesion in the medial lobe (arrowheads) of the deep digital flexor tendon.

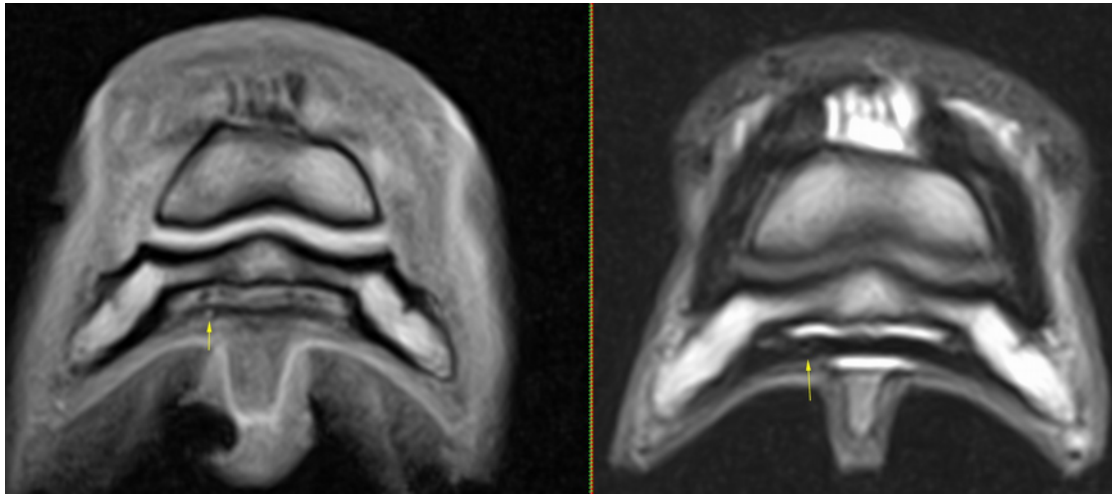


Reported by VetCT

t. +44 (0)1223 422251 www.vet-ct.com e. info@vet-ct.com

Co Number 6955449 Registered Office VetCT, Broers Building, 21 JJ Thomson Avenue, Cambridge, CB3 0FA, United Kingdom
ABN 24601862220 Registered Office in Australia Suite 11, 185-187 High Street Fremantle WA 6160 Australia

This report is based on the available history and radiographic interpretation only and not on a physical examination of the patient. It has been prepared specifically for interpretation by the currently licensed and registered veterinary surgeon responsible for the care of this patient.

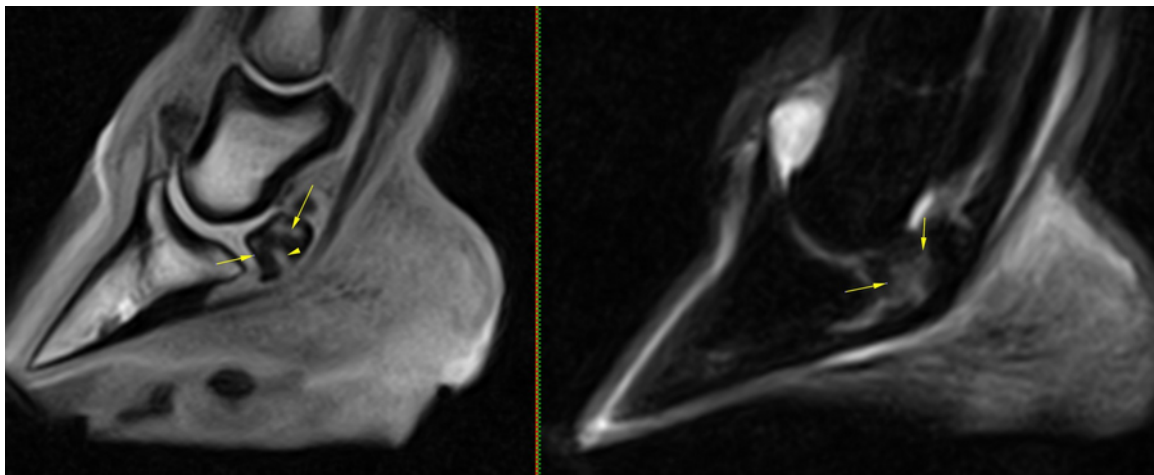


Transverse T1W GRE and T2W FSE sequences showing the focal insertional lesion in the medial lobe of the deep digital flexor tendon – subacute/chronic in nature.

Right foot:

A large T1W and T2W hyperintense lesion extends deeply into the spongiosa of the navicular bone from the level of the distal third of the sagittal ridge. Hyperintensity in T2W FSE and STIR sequences is seen within the palmar cortex at this level. The lesion is surrounded by a much larger area of reduced T1 and T2*W signal intensity and increased STIR signal intensity which involves almost the entire dorsopalmar depth of the bone axially.

A T1 hyperintense parasagittal split is seen palmar to the navicular bone. The navicular bursa is moderately effused. No active lesions of the deep digital flexor tendon are identified in this limb. The medial collateral ligament of the distal interphalangeal joint has similar appearance to that of the left limb.



Sagittal T1W GRE and STIR sequences showing the hyperintensity associated with the flexor cortex of the navicular bone (arrowhead) and the surrounding signal alteration (arrows).



Reported by VetCT

t. +44 (0)1223 422251 www.vet-ct.com e. info@vet-ct.com

Co Number 6955449 Registered Office VetCT, Broers Building, 21 JJ Thomson Avenue, Cambridge, CB3 0FA, United Kingdom
ABN 24601862220 Registered Office in Australia Suite 11, 185-187 High Street Fremantle WA 6160 Australia

This report is based on the available history and radiographic interpretation only and not on a physical examination of the patient. It has been prepared specifically for interpretation by the currently licensed and registered veterinary surgeon responsible for the care of this patient.

Conclusions:

- Active lateral lobe deep digital flexor tendinopathy in the left limb in the presesamoidean area.
- Secondary navicular bursa effusion.
- Subacute/chronic tendinopathy affecting the medial lobe in the left limb.
- Large erosion of the palmar compact bone of the navicular bone in the RIGHT limb with evidence of surrounding bone oedema.
- Bilateral mild desmopathy of the medial collateral ligament of the distal interphalangeal joint.

Additional comments:

- The lesion in the lateral lobe of the deep digital flexor tendon is the most likely cause for the current lameness observed.
- Despite no lameness is currently seen in the right limb the navicular bone pathology observed is unlikely to be incidental.

If you have any queries regarding this report then please "Add a comment" on the VetCT platform or contact info@vet-ct.com



Reported by VetCT

t. +44 (0)1223 422251 www.vet-ct.com **e.** info@vet-ct.com

Co Number 6955449 Registered Office VetCT, Broers Building, 21 JJ Thomson Avenue, Cambridge, CB3 0FA, United Kingdom

ABN 24601862220 Registered Office in Australia Suite 11, 185-187 High Street Fremantle WA 6160 Australia

This report is based on the available history and radiographic interpretation only and not on a physical examination of the patient. It has been prepared specifically for interpretation by the currently licensed and registered veterinary surgeon responsible for the care of this patient.



Reporting Service: XR

Species: Reptile/Amphibian Breed: Lizard - Other Sex: Male Entire Age: 4 years, 11 months

Clinical History:

1 month history of lethargy and hyporexia, 1 week progressive history of open mouth breathing. Oral mucosal edema on PEx, three heart sounds/beat on doppler

Number of series / images: 1 / 6

Series: U_WHOLE_BODY_LIZARD_DV

Study dated: 12/04/2021

Study received: 13/04/2021

Anatomic regions: Thorax, Head, Pelvis/tail, Abdomen

Details of study and technical comments: orthogonal radiographic images of the whole body and skull are presented for interpretation.

Diagnostic interpretation:

Skeletal structures

There is exophytic bone of the entire spine which involves bridging heterogeneous new bone formation of the vertebral bodies at their lateral aspects that is confluent with the process joints and costovertebral articulations and along many of the ribs. Periosteal bone is present along multiple ribs on the left and right. The new bone formation appears like a cuff of exophytic bone that is continuous with the costovertebral joints. The vertebral body margins are effaced by the amount of new bone formation present. The cranial and mid-thoracic segments are the worst affected. The vertebral endplates are indistinct along the entire spine.

The extremities have subjectively decreased bone opacity but have good cortical bone structure and there is no evidence of osteoarthritis of the extremity joints. The left femoral head is poorly visible



Reported by VetCT

t. +44 (0)1223 422251 www.vet-ct.com e. info@vet-ct.com

Co Number 6955449 Registered Office St John's Innovation Centre Cowley Road Cambridge CB4 0WS UK

ABN 24601862220 Registered Office in Australia Suite 11, 185-187 High Street Fremantle WA 6160 Australia

This report is based on the available history and radiographic interpretation only and not on a physical examination of the patient. It has been prepared specifically for interpretation by the currently licensed and registered veterinary surgeon responsible for the care of this patient.

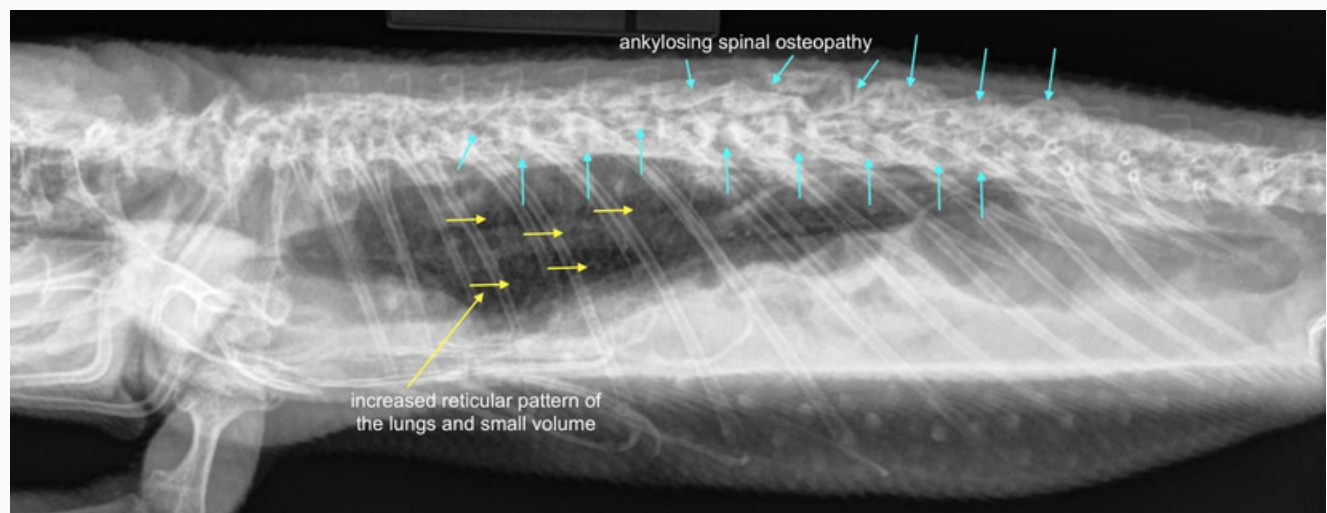
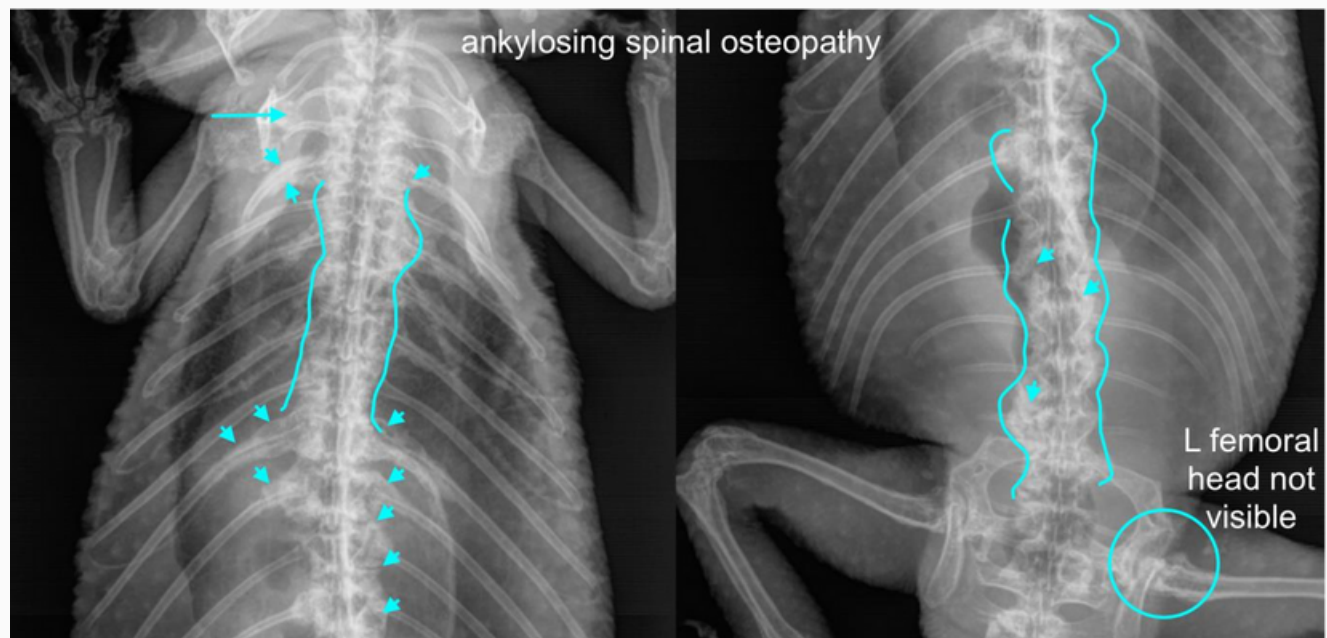and the joint space with the acetabulum is increased in size. The femoral head on the left cannot be well identified in any view. The right coxofemoral joint is comparatively normal. The skull has a subjectively normal bone structure. There are no abnormalities associated with the oral cavity. There are no soft tissue swelling is associated with the skull.

Coelomic cavity

There is a typical lack of serosal detail found in this species. Some of the intestinal structures are gas dilated. There is no evidence of a space occupying lesion.

Respiratory tract

The trachea and nasopharynx are unremarkable. The heart size and location are normal. The primary bronchi are visible and unremarkable. There is a subjective increased opacity of the lung with an increased reticular structure. The size of the air chambers is subjectively reduced.



Reported by VetCT

t. +44 (0)1223 422251 www.vet-ct.com e. info@vet-ct.com

Co Number 6955449 Registered Office St John's Innovation Centre Cowley Road Cambridge CB4 0WS UK

ABN 24601862220 Registered Office in Australia Suite 11, 185-187 High Street Fremantle WA 6160 Australia

This report is based on the available history and radiographic interpretation only and not on a physical examination of the patient. It has been prepared specifically for interpretation by the currently licensed and registered veterinary surgeon responsible for the care of this patient.

Conclusions:

- Proliferative generalized spinal osteopathy is present. This disease has several different causes which include nutritional (hypovitaminosis D and hypervitaminosis A, prolonged inactivity, bacterial and viral infectious etiologies, metabolic bone disease, and immune mediated disease. The proliferative bone affects all vertebral segments, intervertebral spaces/endplates, costovertebral joints, ribs, and articular process joints to the degree that it is ankylosing.
- The skull is unremarkable.
- The lung volume is subjectively reduced and with an associated increased reticular pattern. Differentials for this finding include normal (artifact of superimposition) and lower respiratory infection or fibrosis. There is no evidence of soft tissue consolidations in the lungs. Further diagnostics to assess the lungs may require CT or bronchoscopy with airway sampling. CT can help to assess both the upper and lower airways to determine the cause of the open mouth breathing.

Additional comments:

The cause of the edema in the oral cavity is not evident radiographically. Open mouth breathing can certainly be due to upper or lower airway disease as well as pain in this species. Spinal pain is a consideration given the extensive nature of the spinal osteopathy. Spinal osteopathy can be associated with pain and lethargy in reptiles.

If you have any queries regarding this report then please "Add a comment" on the VetCT platform or contact info@vet-ct.com



Reported by VetCT

t. +44 (0)1223 422251 **www.vet-ct.com** **e.** info@vet-ct.com

Co Number 6955449 Registered Office St John's Innovation Centre Cowley Road Cambridge CB4 0WS UK

ABN 24601862220 Registered Office in Australia Suite 11, 185-187 High Street Fremantle WA 6160 Australia

This report is based on the available history and radiographic interpretation only and not on a physical examination of the patient. It has been prepared specifically for interpretation by the currently licensed and registered veterinary surgeon responsible for the care of this patient.



Reporting Service: PPE

Species: Equine

Breed: Warmblood

Sex: Colt

Age: 5 years

Clinical History:

Pre-purchase exam for jumping up to 3'6". Possible re-sale in the future. Sound during lameness exam but appears stiff behind. Mild positive to hind upper limb flexion.

Questions to be answered:

Number of series / images: 27 / 32

Series: CERVICAL SPINE CAUDAL, CERVICAL SPINE CRANIAL, CERVICAL SPINE MIDDLE, LEFT FORE FOOT DP, LEFT FORE FOOT LATERAL, LEFT FORE FOOT P3 SOLAR MARGINS, LEFT FORE NAVICULAR DP, LEFT FORE NAVICULAR SKYLINE, LEFT STIFLE CACR, LEFT STIFLE LATERAL, LEFT STIFLE OBLIQUE, LEFT TARSUS DLPLO, LEFT TARSUS DMPLO, LEFT TARSUS DP, LEFT TARSUS LATERAL, RIGHT FORE FOOT DP, RIGHT FORE FOOT LATERAL, RIGHT FORE FOOT NAVICULAR DP, RIGHT FORE FOOT NAVICULAR SKYLINE, RIGHT FORE FOOT P3 SOLAR MARGINS, RIGHT STIFLE CACR, RIGHT STIFLE LATERAL, RIGHT STIFLE OBLIQUE, RIGHT TARSUS DLPLO, RIGHT TARSUS DMPLO, RIGHT TARSUS DP, RIGHT TARSUS LATERAL

Anatomic regions: Cervical spine, Stifle - Left, Stifle - Right, Tarsus - Right, Tarsus - Left, Front foot/pastern - Left, Front foot/pastern - Right

Details of study and technical comments: LL images of the cervical spine; LM, CdCr and CdLCrMO views of the stifles; LM, DP, DLPLO, DMPLO of the tarsi; LM, DP, DPrPaDiO and PaPrPaDiO of the front feet. In the left foot a digital and actual marker are present on opposite sides of the limb. The digital marker is considered correctly placed on the lateral side of the limb. Images are of good diagnostic quality.

Diagnostic interpretation:

Cervical spine:

The intervertebral foramina are subjectively narrowed at all visible sites. This is likely secondary to conformation and short vertebral pedicles. The intra and intervertebral ratio are within normal limits.



Reported by VetCT

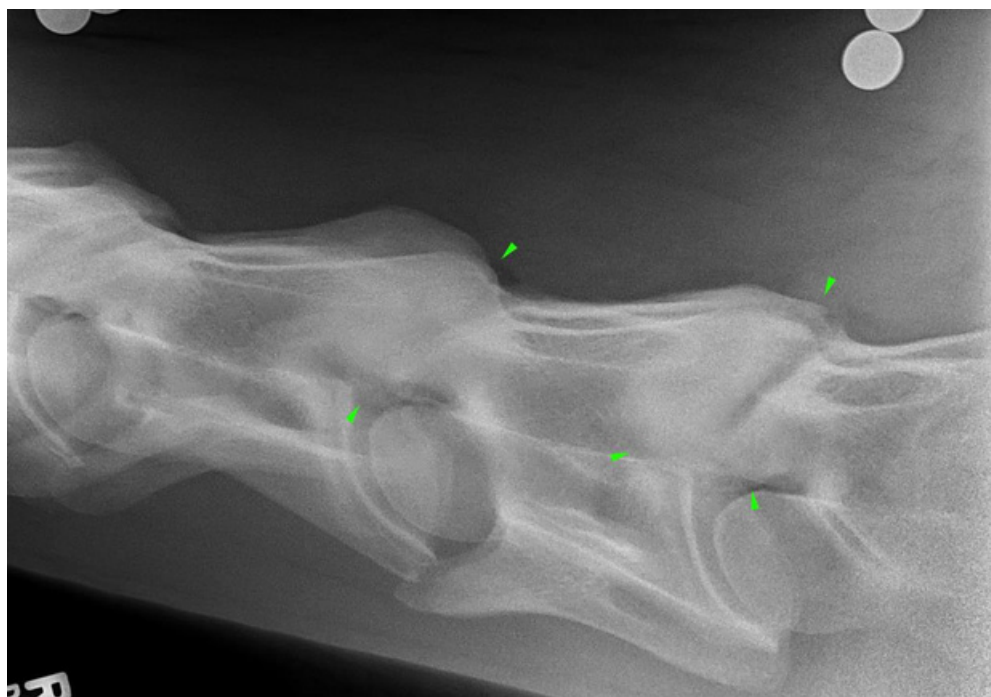t. +44 (0)1223 422251 www.vet-ct.com e. info@vet-ct.com

Co Number 6955449 Registered Office St John's Innovation Centre Cowley Road Cambridge CB4 0WS UK

ABN 24601862220 Registered Office in Australia Suite 11, 185-187 High Street Fremantle WA 6160 Australia

This report is based on the available history and radiographic interpretation only and not on a physical examination of the patient. It has been prepared specifically for interpretation by the currently licensed and registered veterinary surgeon responsible for the care of this patient.

The articular process joints of C5-6 and C6-7 are mild and moderately enlarged respectively. This is symmetric between left and right.



LL view of the caudal cervical spine showing the enlarged C5-6 and C6-7.

Stifles:

Left – There is mild new bone formation on the medial aspect of the tibial plateau. The medial eminence of the tibia is pointy.

Right – a medium size osteophyte is present on the medial aspect of the tibial plateau; the distal articular margin of the medial condyle of the femur is also remodelled. A concavity is present in the distal aspect of the medial condyle. There is thickening of the adjacent subchondral bone but an osseous cyst-like lesion cannot be seen in these images.



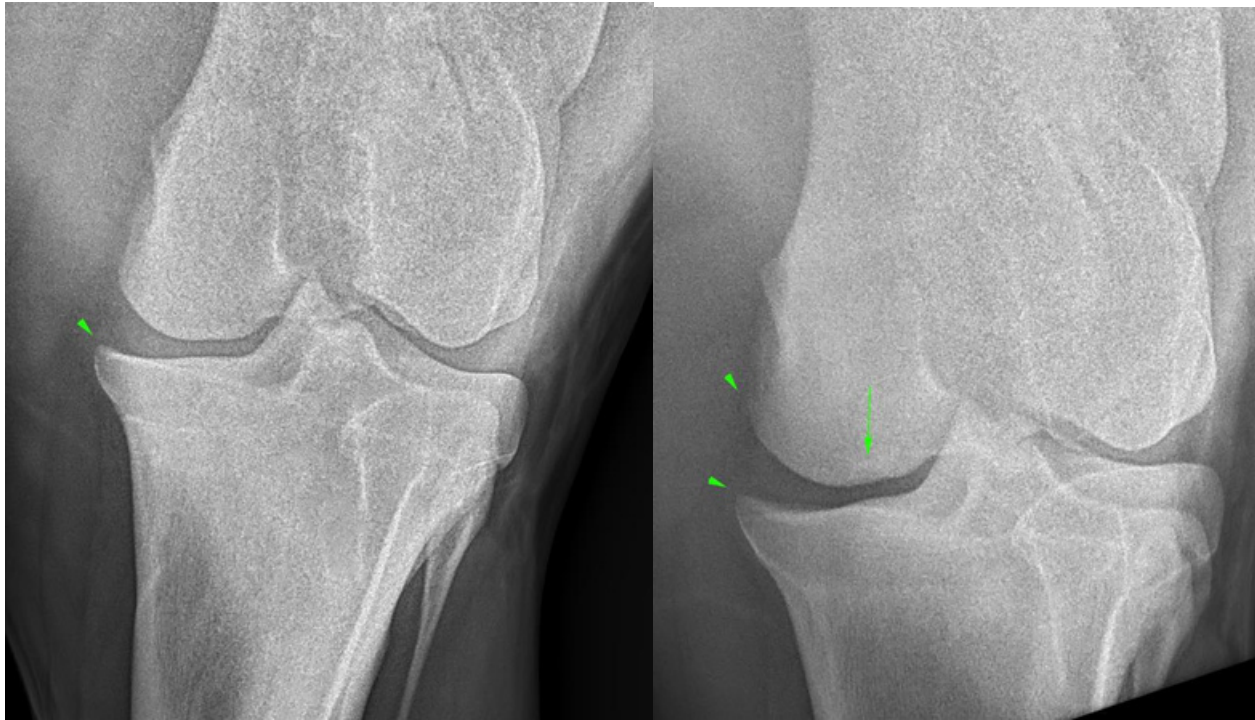
Reported by VetCT

t. +44 (0)1223 422251 www.vet-ct.com e. info@vet-ct.com

Co Number 6955449 Registered Office St John's Innovation Centre Cowley Road Cambridge CB4 0WS UK

ABN 24601862220 Registered Office in Australia Suite 11, 185-187 High Street Fremantle WA 6160 Australia

This report is based on the available history and radiographic interpretation only and not on a physical examination of the patient. It has been prepared specifically for interpretation by the currently licensed and registered veterinary surgeon responsible for the care of this patient.



CdCr views of the left (left side) and right (right side) stifles showing the periarticular remodelling (arrowheads) and the lucency in the RIGHT medial femoral condyle.

Tarsi:

Left – There is narrowing of the distal intertarsal joint. The subchondral bone of both the third and central tarsal bone is thickened. Subchondral bone lucencies are present in both bones dorsomedially. The interosseous space of the distal intertarsal joint is not visible and markedly increased in opacity. Moderate periarticular remodelling is present associated with the distal intertarsal joint dorsolaterally.

Right – There is a similar appearance of the distal intertarsal joint to that of the left limb but the degree of subchondral bone lysis is less severe in this limb.



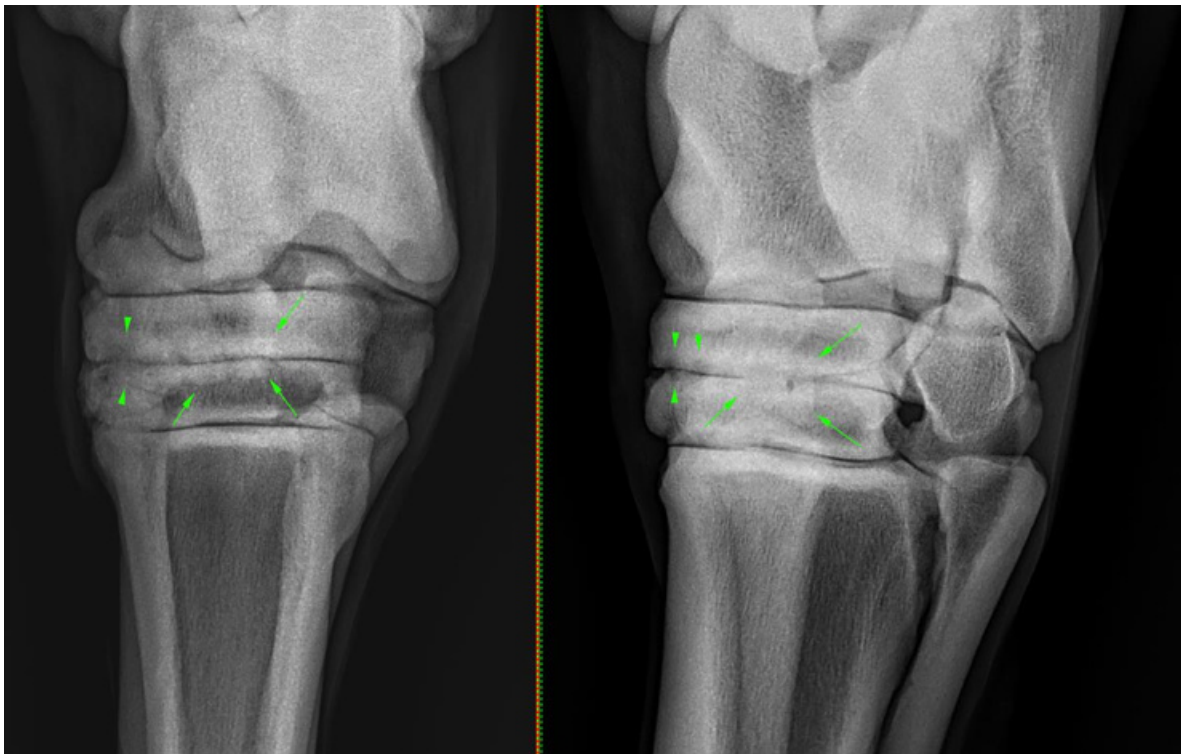
Reported by VetCT

t. +44 (0)1223 422251 www.vet-ct.com e. info@vet-ct.com

Co Number 6955449 Registered Office St John's Innovation Centre Cowley Road Cambridge CB4 0WS UK

ABN 24601862220 Registered Office in Australia Suite 11, 185-187 High Street Fremantle WA 6160 Australia

This report is based on the available history and radiographic interpretation only and not on a physical examination of the patient. It has been prepared specifically for interpretation by the currently licensed and registered veterinary surgeon responsible for the care of this patient.



DP and DLPMO views of the LEFT tarsus showing the subchondral bone lucencies (arrowheads) and the sclerosis of the interosseous space of the distal intertarsal joint (arrows).

Front feet:

Left – the palmar compact bone of the navicular bone is subjectively thickened in the LM view but normal in the skyline view. This may reflect slight obliquity in the LM view. A possible small distal border fragment is present at the junction between the distal horizontal and lateral sloping borders. Only a small defect is seen in the adjacent navicular bone.

The toe is long. The medial hoof wall is upright while the lateral is flared.

Right – two triangular shaped synovial invaginations are seen along the distal horizontal border of the navicular bone.

There is similar foot conformation to that of the left limb.

Conclusions:

- Moderate bilateral osteoarthritis of the distal intertarsal joint
- Osteoarthritis of the medial femorotibial joint; mild in the left limb and moderate in the right.
- Subchondral bone lucency in the RIGHT medial femoral condyle.
- Possible small distal border fragment in the LEFT navicular bone.
- Symmetrical enlargement of the caudal articular process joints.



Reported by VetCT

t. +44 (0)1223 422251 www.vet-ct.com e. info@vet-ct.com

Co Number 6955449 Registered Office St John's Innovation Centre Cowley Road Cambridge CB4 0WS UK

ABN 24601862220 Registered Office in Australia Suite 11, 185-187 High Street Fremantle WA 6160 Australia

This report is based on the available history and radiographic interpretation only and not on a physical examination of the patient. It has been prepared specifically for interpretation by the currently licensed and registered veterinary surgeon responsible for the care of this patient.

Additional comments:

The most concerning finding for future soundness and re-sale value of this horse are found in the stifles and tarsi. The degree of osteoarthritis seen in all these regions could progress to overt lameness although successful management of these conditions may be achieved.

The degree of osteoarthritis in the cervical spine is relatively mild and likely reflects adaptive remodelling at this stage.

The distal border fragment in the navicular bone is very small and its clinical significance per se is difficult to determine.

If you have any queries regarding this report then please "Add a comment" on the VetCT platform or contact info@vet-ct.com



Reported by VetCT

t. +44 (0)1223 422251 **www.vet-ct.com** **e.** info@vet-ct.com

Co Number 6955449 Registered Office St John's Innovation Centre Cowley Road Cambridge CB4 0WS UK

ABN 24601862220 Registered Office in Australia Suite 11, 185-187 High Street Fremantle WA 6160 Australia

This report is based on the available history and radiographic interpretation only and not on a physical examination of the patient. It has been prepared specifically for interpretation by the currently licensed and registered veterinary surgeon responsible for the care of this patient.



Reporting Service: XR

Species: Caprine Breed: Other Sex: Female Entire Age: 1 month

Clinical History:

4 week old goat rescued approximately 1 week ago; bottle fed by owner and admitted to RDVM for lethargy, concern re: AP but rads at that time showed only mild changes. Acute worsening of RR and RE today; recheck rads (approx 4 days after RDVM films).

Questions to be answered:

Concern for significant pneumonia. Other abnormalities noted?

Number of series / images: 4 / 4

Series: [DV_THORAX, LEFT LATERAL THORAX, RIGHT LATERAL THORAX]

Study dated: 21/04/2020

Study received: 21/04/2020

Anatomic regions: Thorax

Details of study and technical comments: A radiographic study of the thorax is available for interpretation. The study includes left and right lateral views and two dorsoventral views. The study is of diagnostic quality.

Diagnostic interpretation:

The cardiac silhouette is obscured by a soft tissue opacity containing some small air bronchograms. There is a lobar sign at the caudal aspect of this soft tissue opacity (alveolar pattern). In the mid aspect of the dorsal half of the lung field there are some alveolar patches detected.

Several rounded, well-margined gas opacities are present in the caudal aspect of the thorax, partly superimposed over the consolidated lung lobe obscuring the cardiac silhouette. These gas opacities are of different sizes (diameters varying from 4 mm tot 12 mm). In the cranioventral aspect of the thorax there is a larger gas filled tubular structure detected (diameter of 8 mm). The mid aspect of the



Reported by VetCT

t. +44 (0)1223 422251 www.vet-ct.com e. info@vet-ct.com

Co Number 6955449 Registered Office St John's Innovation Centre Cowley Road Cambridge CB4 0WS UK

ABN 24601862220 Registered Office in Australia Suite 11, 185-187 High Street Fremantle WA 6160 Australia

This report is based on the available history and radiographic interpretation only and not on a physical examination of the patient. It has been prepared specifically for interpretation by the currently licensed and registered veterinary surgeon responsible for the care of this patient.

diaphragm is difficult to delineate. On the ventrodorsal view these gas filled structures are arranged around the cardiac silhouette.

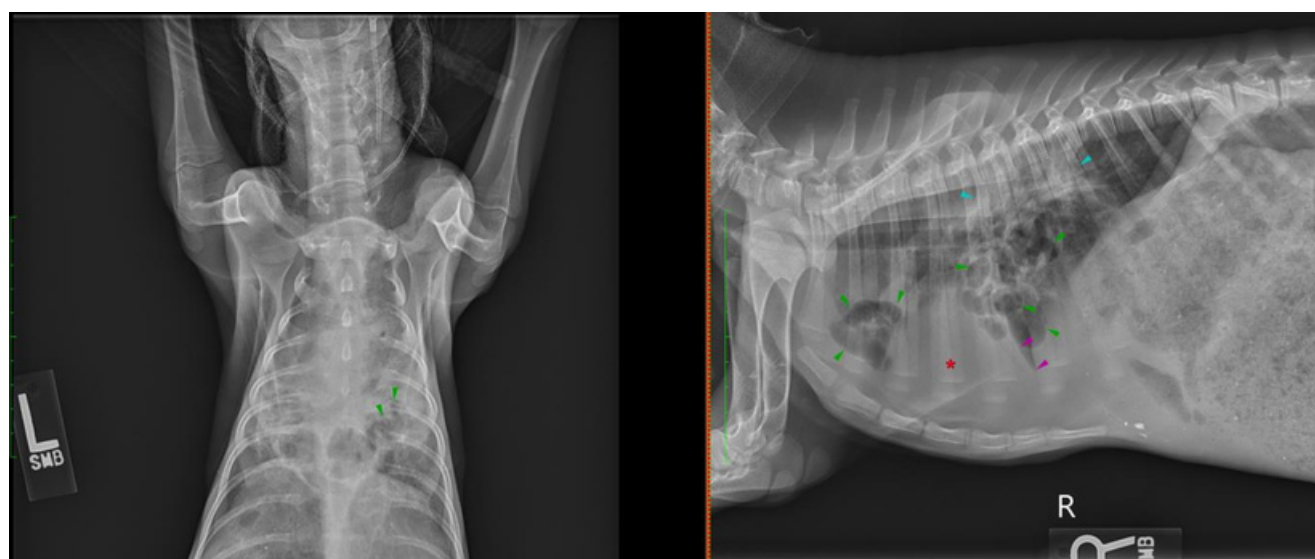


Figure 1: dorsoventral and right lateral projection of the thorax. The green arrowheads indicate the rounded and tubular gas filled structures. The red asterisk indicates the consolidated lung obscuring the cardiac silhouette. The pink arrowheads indicate the lobar sign of this consolidated lung. The cyan arrowheads indicate smaller alveolar patches in the dorsal aspect of the lung field.

Conclusions:

- Lobar pneumonia with a ventral distribution: aspiration pneumonia is most likely considering the anamnesis, however bacterial bronchopneumonia cannot completely be excluded.
- Suspicion of diaphragmatic hernia: congenital origin or traumatic origin.

Additional comments:

The presence of the pneumonia explains the respiratory symptoms.

A diaphragmatic hernia is strongly suspected, the organisation of the gas filled structures around the cardiac silhouette on the ventrodorsal projection could suggest a peritoneo-pericardial diaphragmatic hernia. This type of hernia would however demonstrate better defined margins, however this might be obscured by the alveolar opacifications due to the pneumonia. Ultrasonography of the thorax is advised for identification of and localisation of the intestinal structures.

Reporting Radiologist:

If you have any queries regarding this report then please "Add a comment" on the VetCT platform or contact info@vet-ct.com



Reported by VetCT

t. +44 (0)1223 422251 www.vet-ct.com e. info@vet-ct.com

Co Number 6955449 Registered Office St John's Innovation Centre Cowley Road Cambridge CB4 0WS UK

ABN 24601862220 Registered Office in Australia Suite 11, 185-187 High Street Fremantle WA 6160 Australia

This report is based on the available history and radiographic interpretation only and not on a physical examination of the patient. It has been prepared specifically for interpretation by the currently licensed and registered veterinary surgeon responsible for the care of this patient.



Reporting Service: CT

Species: Equine Breed: Appaloosa Sex: Male Neutered Age: 14 years, 2 months

Clinical History:

Chronic RF lameness, previously responsive to medication of distal interphalangeal joint. Now 3-4/5 RF lameness. Positive to distal interphalangeal joint block but no improvement to medication. Foot radiographs were overly unremarkable – suspect soft tissue lesion RF.

Questions to be answered:

Number of series / images: 4 / 1946

Series: EXTR.PFERD KM 1.0 B31S, EXTR.PFERD KM 1.0 B70S, FORE RIGHT / LEFT 1.0 B31S, FORE RIGHT/LEFT 1.0 B70S

Anatomic regions: Front fetlock - Left, Front fetlock - Right, Front foot/ pastern - Left, Front foot/ pastern - Right

Details of study and technical comments: Computed tomographic imaging studies of the fore limb digits are available for review. The study includes native images of both fore limbs and a post contrast series of the right fore limb. The images are reconstructed in bone and soft tissue algorithms and are of good diagnostic quality.

Diagnostic interpretation:

- The left fore limb:

There is markedly extensive subchondral bone sclerosis and chronic periarticular osteophytosis of the metacarpophalangeal joint, which is circumferential but predominantly affects the medial and dorsomedial aspect of the joint and involves both phalangeal and metacarpal aspects. The articular surface of the metacarpophalangeal joint is somewhat irregular, though a reconstruction 'step' artefact affects detailed evaluation of the articular surface. Apical and basilar remodelling affects both medial and lateral proximal sesamoid bones but is rather mild.



Reported by VetCT

t. +44 (0)1223 422251 www.vet-ct.com e. info@vet-ct.com

Co Number 6955449 Registered Office St John's Innovation Centre Cowley Road Cambridge CB4 0WS UK

ABN 24601862220 Registered Office in Australia Suite 11, 185-187 High Street Fremantle WA 6160 Australia

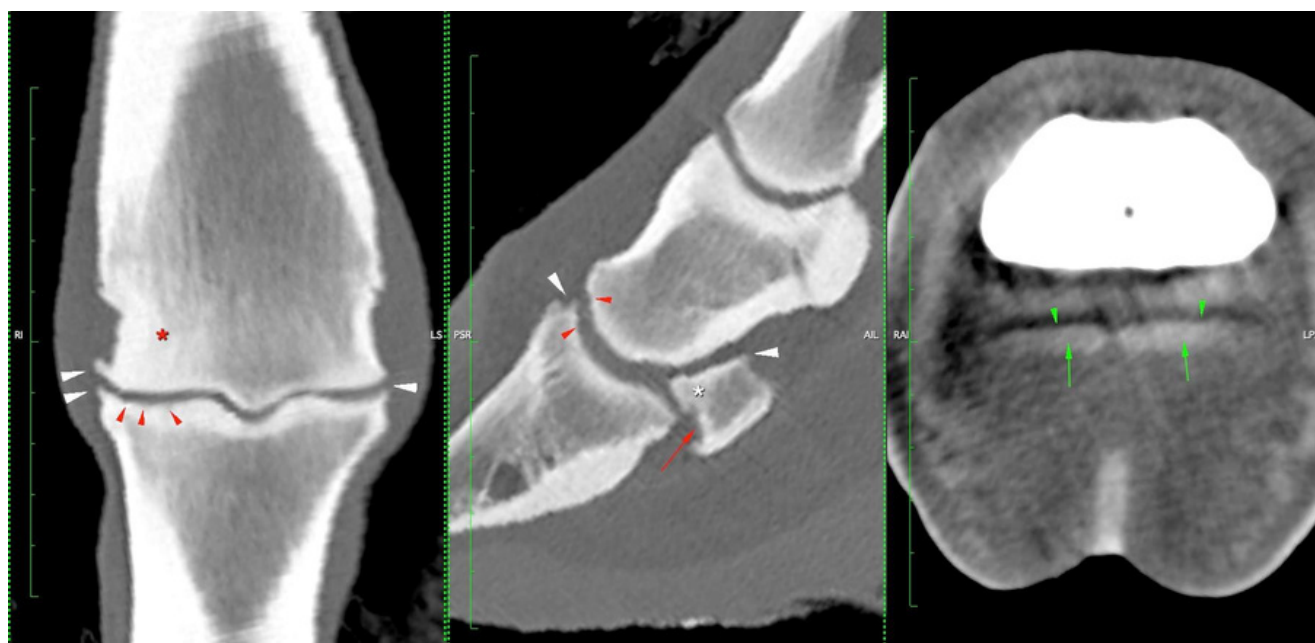
This report is based on the available history and radiographic interpretation only and not on a physical examination of the patient. It has been prepared specifically for interpretation by the currently licensed and registered veterinary surgeon responsible for the care of this patient.

Moderate chronic / active periarticular osteophytosis also affects the proximal interphalangeal joint with moderate but symmetric subchondral bone sclerosis.

The dorsal and palmar margins of the distal interphalangeal joint are chronically remodelled. Osteophytes are present on the dorsal articular margin. The subchondral bone has irregular chondral and endosteal borders. The skin contour suggests mild filling of the dorsal recess. There is moderate osseous remodelling at the proximal entheses of the collateral ligaments of the distal interphalangeal joint, the collateral fossae of the distal phalanx are mildly remodelled but have smooth compact bone and are not enlarged.

The navicular bone is morphologically altered with rounding of the proximo palmar angle, osteophytosis of the dorso proximal angle and mild to moderate distal border remodelling. There remains good definition between the spongiosa, and flexor compact bone and no overt flexor surface defects are detectable. Sclerosis of the spongiform bone in the dorsodistal angle of the navicular bone is noted.

Soft tissue reconstructions of the data show no overt evidence of soft tissue abnormalities within the imaging volume.



Left image: frontal bone reformat of the left metacarpophalangeal joint showing marked periarticular osteophytes (white arrowheads), an irregular subchondral bone surface (red arrowheads) and subchondral bone sclerosis (red asterisk). **Centre image:** sagittal bone reformat of the left fore foot to illustrate the periarticular osteophytes (white arrowheads), irregular subchondral bone surface (red arrowheads), remodelling distal border of the navicular bone (red arrow) and sclerosis of the navicular spongiform bone (white asterisk). **Right image:** transverse soft tissue reformat of the left fore foot showing a normal appearance of the navicular bursa (green arrowheads) and deep digital flexor tendon (green arrows).

- The right fore limb:

The pattern of subchondral bone sclerosis and periarticular osteophytosis of the metacarpophalangeal joint is similar in the right fore to that described above for the left fore but is less extensive and less advanced. Again, the medial and dorsomedial aspects of the joint are predominantly affected. The



Reported by VetCT

t. +44 (0)1223 422251 www.vet-ct.com e. info@vet-ct.com

Co Number 6955449 Registered Office St John's Innovation Centre Cowley Road Cambridge CB4 0WS UK

ABN 24601862220 Registered Office in Australia Suite 11, 185-187 High Street Fremantle WA 6160 Australia

This report is based on the available history and radiographic interpretation only and not on a physical examination of the patient. It has been prepared specifically for interpretation by the currently licensed and registered veterinary surgeon responsible for the care of this patient.

articular surface of the metacarpophalangeal joint is again somewhat irregular, though no overt subchondral defects are detected bearing in mind the mild reconstruction artefact inherent to the images. Apical and basilar remodelling affects both medial and lateral proximal sesamoid bones but is mild.

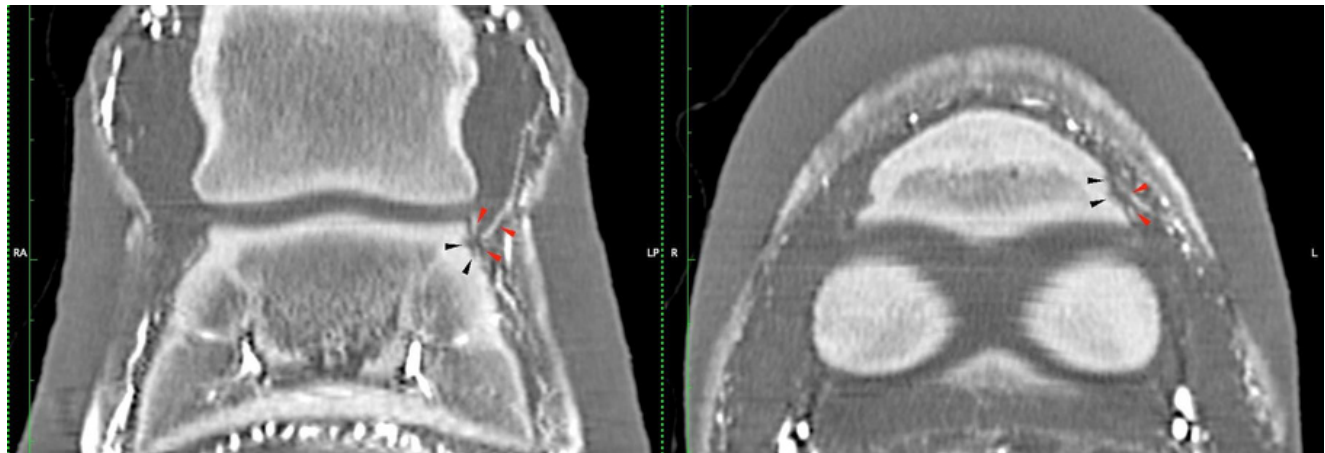
The proximal interphalangeal joint is unremarkable in this limb.

Regarding the foot, the distal interphalangeal joint is less remodelled in this limb with mild dorsal periarticular osteophytes. The subchondral bone plate is subjectively somewhat smoother, though mild articular irregularity is a feature here also. There is no evidence of synovial distension. There is mild focal osseous remodelling of the medial collateral fossa of the distal phalanx at the enthesis of the medial collateral ligament of the distal interphalangeal joint.

The navicular bone has a similar appearance to that described for the left fore with moderate distal border remodelling, mild rounding of the proximal palmar angle, mild dorsal sclerosis of the spongiform bone but good definition between the spongiforma and palmar compact bone with no evidence of flexor surface pathology.

- Post contrast images of the right fore limb:

There is moderate enhancement within the distal third of the medial collateral ligament of the distal interphalangeal joint at the enthesis associated with the osseous remodelling of the medial collateral fossa consistent with a chronic, active enthesiopathy / desmopathy of the medial collateral ligament.



Frontal and transverse post contrast images of the right fore foot. Medial is to the right of the images. There is osseous remodelling of the medial collateral fossa (black arrowheads) and enhancement within the distal attachment of the medial collateral ligament (red arrowheads).

The post contrast images show no detectable abnormal enhancement of the and deep digital flexor tendon, the ligaments of the palmar pastern and the soft tissue structures of the metacarpophalangeal joint region. There is, subjectively, mild hypervascularity within the synovium of the proximal recess of the navicular bursa and the epitenon of the deep digital flexor tendon at the same location. The significance of this is questionable in the absence of overt tendon injury or bursal distension.



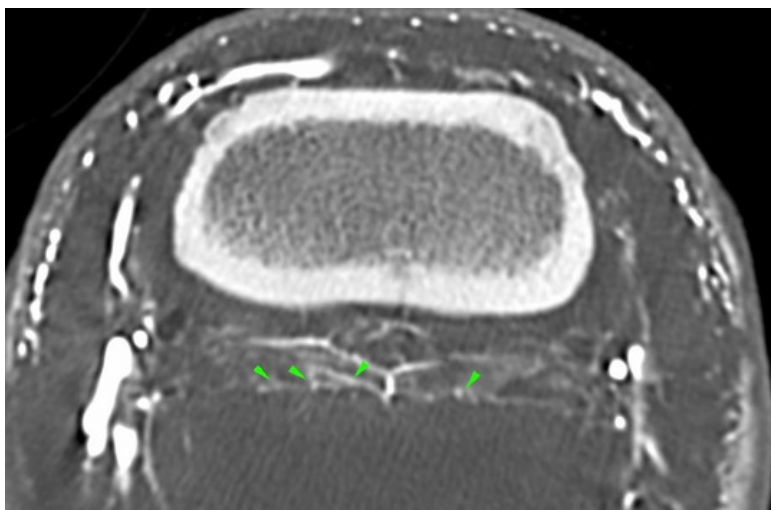
Reported by VetCT

t. +44 (0)1223 422251 www.vet-ct.com e. info@vet-ct.com

Co Number 6955449 Registered Office St John's Innovation Centre Cowley Road Cambridge CB4 0WS UK

ABN 24601862220 Registered Office in Australia Suite 11, 185-187 High Street Fremantle WA 6160 Australia

This report is based on the available history and radiographic interpretation only and not on a physical examination of the patient. It has been prepared specifically for interpretation by the currently licensed and registered veterinary surgeon responsible for the care of this patient.



Post contrast transverse reformatted image at the level of the proximal recess of the bursa. There is subjective hypervascularity in the region of the navicular bursa and epitenon of the deep digital flexor tendon (green arrowheads).

Conclusions:

1. Chronic, active enthesiopathy / desmopathy of the medial collateral ligament of the distal interphalangeal joint of the **right** fore foot.
2. Marked osteoarthritis of the metacarpophalangeal joint in the **left fore** limb, mild osteoarthritis of the **right** metacarpophalangeal joint.
3. Moderate osteoarthritis of the distal interphalangeal joint in the **left** fore limb, mild in the **right** fore limb.
4. Moderate osteoarthritis of the **left** proximal interphalangeal joint. The **right** proximal interphalangeal joint is largely normal.
5. Mild to moderate navicular disease in **both** fore limbs, limited predominantly to chronic remodelling changes. No flexor cortex pathology has been detected in the navicular bone of either fore limb.
6. Mild, subjective hypervascularity of the navicular bursa in the **right** fore foot may indicate low-grade bursitis or normal variation.

Additional comments:

The medial collateral ligament injury is the most likely cause of the persistent **right** fore lameness localised to the region of the distal interphalangeal joint. Osteoarthritis of the distal interphalangeal joint is relatively mild in this limb but may be a contributory factor.

Any observed left fore limb lameness is likely due to osteoarthritis of the metacarpophalangeal joint and / or distal interphalangeal joint, though diagnostic local analgesia would be necessary to confirm the relevance of these findings.

If you have any queries regarding this report then please "Add a comment" on the VetCT platform or contact info@vet-ct.com



Reported by VetCT

t. +44 (0)1223 422251 **www.vet-ct.com** **e.** info@vet-ct.com

Co Number 6955449 Registered Office St John's Innovation Centre Cowley Road Cambridge CB4 0WS UK

ABN 24601862220 Registered Office in Australia Suite 11, 185-187 High Street Fremantle WA 6160 Australia

This report is based on the available history and radiographic interpretation only and not on a physical examination of the patient. It has been prepared specifically for interpretation by the currently licensed and registered veterinary surgeon responsible for the care of this patient.



Reporting Service: XR

Species: Equine Breed: Quarterhorse Sex: Mare Age: 6 years

Clinical History:

Single episode of epistaxis 6 weeks previously. Firm swellings on forehead appeared 2 weeks ago. Clinical parameters normal. Swellings are present biaxially at the medial canthus and are non-painful to palpate

Questions to be answered:

Number of series / images: 5 / 5

Series: SKULL DV, SKULL LEFT LATERAL, SKULL LEFT OBLIQUE, SKULL RIGHT LATERAL, SKULL RIGHT OBLIQUE

Anatomic regions:

Head

Details of study and technical comments:

Laterolateral, oblique and DV views of the head. Images are of good diagnostic quality.

Diagnostic interpretation:

A slight depression in the dorsal aspect of the head is present at the junction between the frontal and nasal bones; periosteal and endosteal reaction is present at this level and also extending to the right and left side along the expected position of the suture line between these two bones. There is moderate soft tissue swelling associated with the lesion involving both the skin surface and the sinuses mucosa. Small gas bubbles are present adjacent to the midline of the lesion, in the subcutaneous tissue, visible in LL views only.

No other changes are seen in the sinuses. The dental elements are normal.



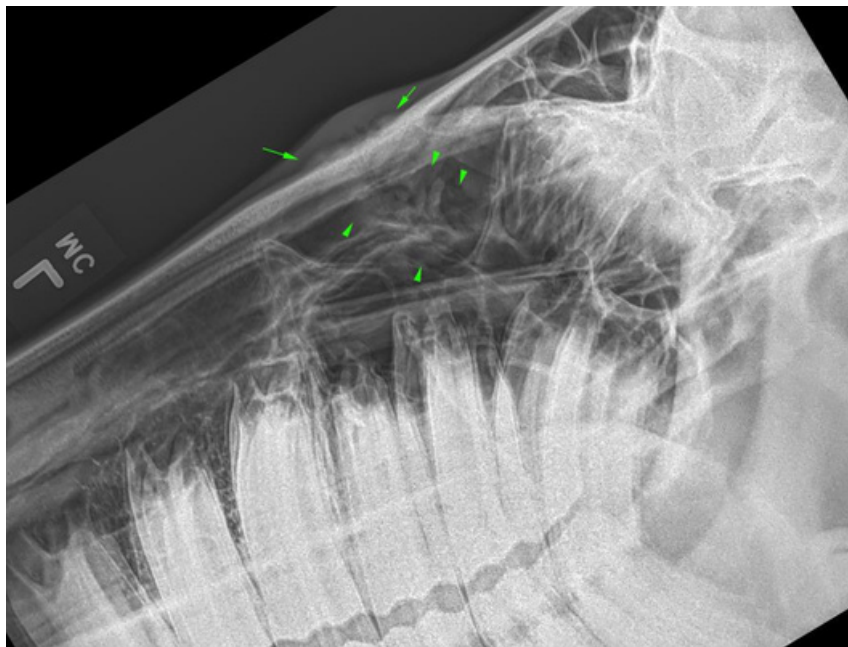
Reported by VetCT

t. +44 (0)1223 422251 www.vet-ct.com e. info@vet-ct.com

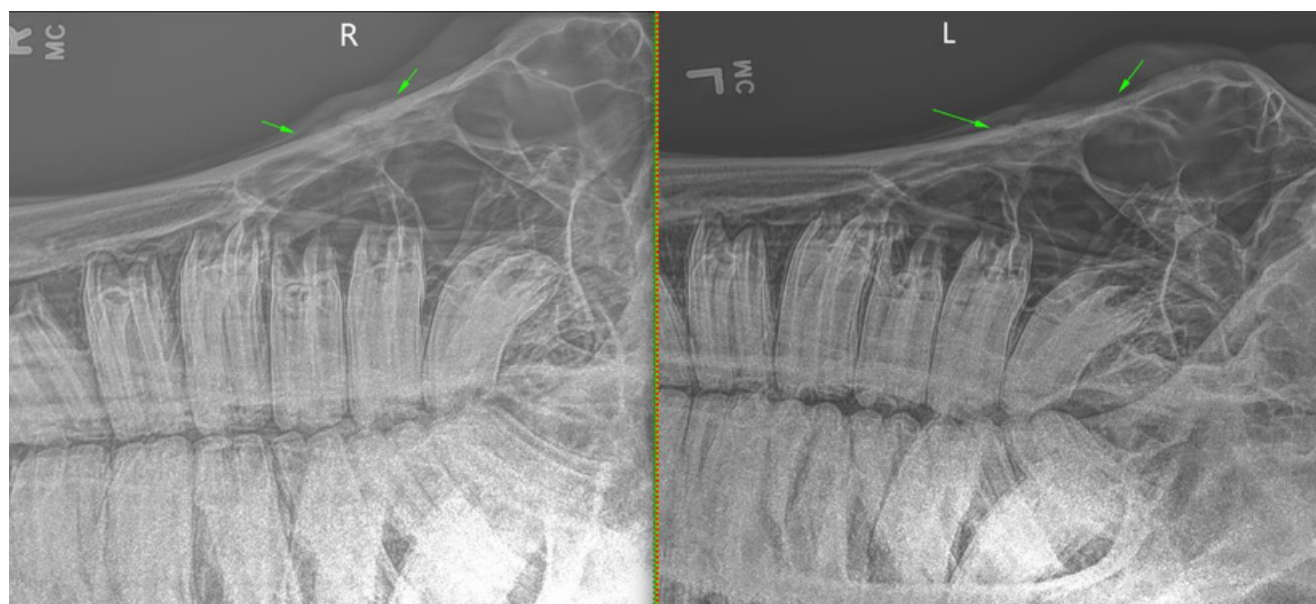
Co Number 6955449 Registered Office St John's Innovation Centre Cowley Road Cambridge CB4 0WS UK

ABN 24601862220 Registered Office in Australia Suite 11, 185-187 High Street Fremantle WA 6160 Australia

This report is based on the available history and radiographic interpretation only and not on a physical examination of the patient. It has been prepared specifically for interpretation by the currently licensed and registered veterinary surgeon responsible for the care of this patient.



LL view showing the dorsal periosteal reaction (arrows) and the location of the abnormalities extending to the left and right of it (arrowheads)



Right and left oblique views showing the periosteal reaction on the right and left side of the midline.

Conclusions:

- Nasofrontal suturitis likely traumatic in origin

Additional comments:

Radiographs have shown presence of periosteal reaction associated with the nasofrontal suture line which is likely secondary to trauma. The gas adjacent to the dorsal aspect of the lesion may be indicative of communication of the subcutis with the sinus system. It is possible that a fracture had

occurred at the time of initial injury to justify the slight depression identified in the nasal bone although a fracture is not currently seen.

If you have any queries regarding this report then please "Add a comment" on the VetCT platform or contact info@vet-ct.com



Reported by VetCT

t. +44 (0)1223 422251 www.vet-ct.com e. info@vet-ct.com

Co Number 6955449 Registered Office St John's Innovation Centre Cowley Road Cambridge CB4 0WS UK

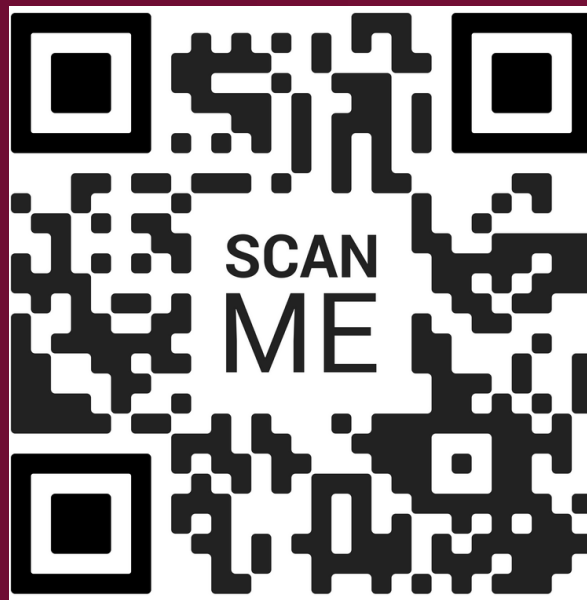ABN 24601862220 Registered Office in Australia Suite 11, 185-187 High Street Fremantle WA 6160 Australia

This report is based on the available history and radiographic interpretation only and not on a physical examination of the patient. It has been prepared specifically for interpretation by the currently licensed and registered veterinary surgeon responsible for the care of this patient.

Connect with us today &

DISCOVER

the VetCT difference



CONTACT US

info@vet-ct.com

vet-ct.com

